

WOVEN ENDOBRIDGE SYSTEM FOR WIDE-NECKED BIFURCATION ANEURYSMS TREATMENT: PRELIMINARY RESULTS OF THE FIRST CENTER IN SOUTHEAST ASIA

Nguyen Huu An^{1,2,✉}, Vu Dang Luu^{1,2}, Tran Anh Tuan², Nguyen Quang Anh^{1,2},
Le Hoang Kien², Nguyen Tat Thien², Nguyen Thu Trang²

¹Hanoi Medical University

²Bach Mai Hospital

This study reports the initial results of wide-necked bifurcation aneurysms treated with Woven EndoBridge (WEB) system at one of the first centers in Southeast Asia from April 2019 to June 2022. A total of 12 patients (50% female, median age of 66) with 12 aneurysms (9 unruptured and 3 ruptured) were recruited. The aneurysms were located in the basilar apex (4 patients), anterior communicating artery (4 patients), middle cerebral artery (3 patients), and posterior cerebral artery (1 patient). The average aneurysm size was 6.3mm (range 4.8 - 8.0mm) with mean dome to neck ratio of 1.2 and mean neck size of 5.4 mm (range 3.7 - 6.9mm). The technique was successful in all cases (100%) without any adjunctive devices. No intraoperative rupture occurred. Thromboembolic complications that occurred in two patients resulted in death in 1 patient (accompanied by retroperitoneal bleeding) (1/12, 8.3%) and moderate disability in 1 patient (1/12, 8.3%). The MRI follow-up at 3 months showed complete occlusion in 6 aneurysms (6/11, 54.5%) and neck remnant in 5 aneurysms (5/11, 45.5%). The study demonstrated that the WEB system alone was feasible to treat both ruptured and unruptured wide-necked bifurcation aneurysms. This device seems to be a promising tool for the treatment of complex wide-necked bifurcation aneurysms.

Keywords: Woven EndoBridge system, cerebral aneurysm, wide-necked bifurcation aneurysm.

I. INTRODUCTION

Subarachnoid hemorrhage (SAH) is a serious medical condition with a 30-day mortality rate of up to 45%.¹ Among cases of non-traumatic SAH, ruptured intracranial aneurysms (RIAs) are responsible for 80% of all cases.¹ Not only there was a high risk of death, but approximately half of survival patients after RIAs were at risk of lifelong disability.¹ Therefore, early detection and treatment of unruptured intracranial aneurysms (UIAs) at high risk of rupture as well as effective treatment of RIAs are essential to

reduce the burden of this pathology.

Wide-necked bifurcation aneurysms (WNBAs) are defined as aneurysm sacs which commonly located in the anterior communicating (Acom), middle cerebral artery (MCA), internal carotid artery terminus (ICAt), and basilar apex (BA) with the dome to neck ratio less than 2 or the neck diameter greater than 4mm.² Although accounting for only 26 to 36% of all IAs, wide-necked bifurcation aneurysms (WNBAs) remain one of the most difficult types of aneurysms to treat and cure permanently.² Aneurysm clipping was supposed to have the highest immediate occlusion and lowest recurrence rates, but it was also a highly invasive method with a complication rate ranging from 24 to 67% of cases.² Additionally, some deep anatomical

Corresponding author: Nguyen Huu An

Hanoi Medical University

Email: nguyenhuuan.dr@gmail.com

Received: 23/08/2022

Accepted: 27/12/2022

locations such as the apex of the basilar artery were also difficult to approach.² Therefore, in the past 20 years, endovascular treatment (EVT) has been developed as a less invasive and safer treatment for IAs.^{3,4} A variety of EVT techniques have been developed to treat WNBAs including intra-aneurysm occlusion (coiling alone, balloon-assisted coiling, stent-assisted coiling), diversion of the flow in the parent artery (flow diverter stent), and most recently intra-aneurysm flow disruption.⁵

Flow disruption with Woven EndoBridge (WEB; Micro Vention, Aliso Viejo, CA, USA) system was a new approach to treating WNBAs.⁵ The safety and efficacy of this device have been well evaluated in prospective, multicenter, Good Clinical Practice (GCP) studies in Europe since 2011 and in the USA since 2019.^{6,7} However, the use of WEB devices for the treatment of WNBAs is still relatively new in Asian countries. Since April 2019, Bach Mai Radiology center is one of the first centers in Southeast Asia to apply the WEB device, to treat WNBAs. Since then, subsequent cases have also been performed, but no study has been conducted to report these treatment results. In this study, we aim to evaluate the preliminary results of the WEB treatment for WNBAs through the first single-center study report in Southeast Asia.

II. METHODS

1. Research subjects

All patients with ruptured or unruptured intracranial aneurysms treated with WEB device at the Radiology center of Bach Mai hospital from April 2019 to June 2022 were recruited for this study. Patient selection criteria were based on the WEB-IT (Woven EndoBridge Intrasaccular Therapy) trial selection criteria conducted in the USA.⁷

Selection criteria included: 1) ruptured or unruptured cerebral aneurysm with the indication for treatment; 2) wide-necked

saccular aneurysm (neck diameter \geq 4mm, or dome/neck ratio $<$ 2); 3) bifurcation location in Acom, MCA, ICAt, BA, or PCA, 4) acceptance to participate in the study.

Exclusion criteria included: 1) acute stroke within one month, 2) severe disability at the time of admission (baseline modified Rankin Scale $>$ 2).

2. Study design

This is a descriptive longitudinal study based on a prospective database of WEB treatment in the Radiology center of Bach Mai Hospital. The sample size of the study was taken by the convenience sampling method from April 2019 to June 2022.

Device characteristics

The WEB-single layer (WEB-SL) (Micro Vention, Aliso Viejo, CA, USA) is a self-expanding, retrievable, electrothermally detachable, nitinol-braided device, which is placed within the aneurysm sac (Figure 1). The device disrupts blood flow at the aneurysm neck and induces intra-aneurysmal thrombosis. WEB devices ranging between 4x3mm and 11x9mm were delivered through VIA 17, 21, 27, and 33 microcatheters (Micro Vention, Aliso Viejo, CA, USA). Contrary to the irregular surface created by the coils at the level of the neck, WEB is offering a flat proximal surface that is potentially better support for the new endothelium (Figure 1).

WEB embolization procedure

The procedure was performed by a senior neurointerventionalist ($>$ 15 years of experience) under a biplane angiographic system (Philips Azurion 7 B20/15) or a monoplane angiographic system (Philips Allura Xper FD20). Patients with ruptured aneurysms were treated under general anesthesia, meanwhile, patients with unruptured aneurysms were treated under local anesthesia. Regarding antiplatelet treatment, patients with unruptured aneurysms received

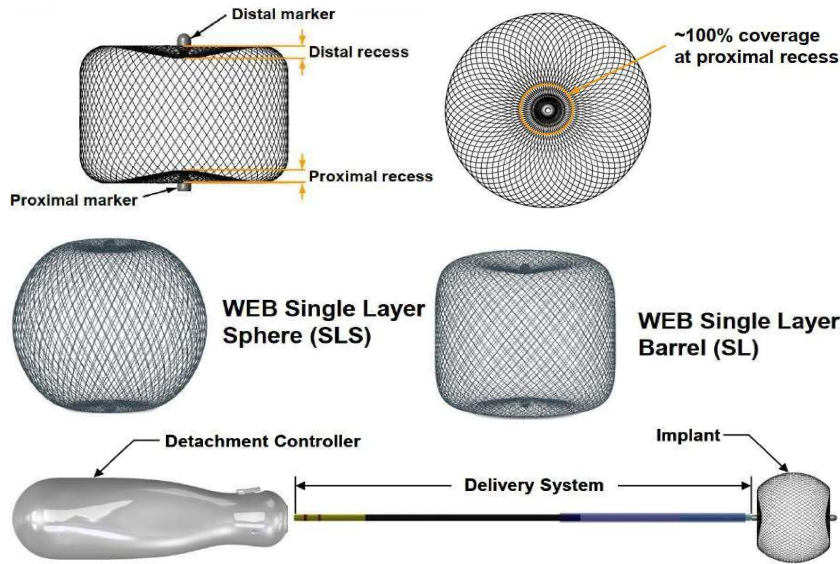


Figure 1. WEB device systems

double antiplatelet therapy (DAPT) a few days before the procedure according to a previous published study.⁸ Two different protocols were successively used: 1/ aspirin 81mg/day and clopidogrel 75mg/day during 5 days and 2/ aspirin 81mg/day and ticagrelor 90mgx2/day during 2 days. Patients with ruptured aneurysms were not required to use antiplatelet therapy before treatment. During the procedure, all patients (with ruptured and unruptured aneurysms) received a loading dose of heparin

(2500 units) after femoral puncture followed by an infusion of 1000 units/h. Postoperatively all patients were receiving aspirin 75mg orally for at least 4 weeks. In case of severe WEB protrusion, clopidogrel or ticagrelor (same doses) was also given with variable durations.

Sizing of the WEB device was performed using measurements done on 3D-DSA images. The size of the aneurysm including width, height, and neck was measured in 2 orthogonal planes (Figure 2).

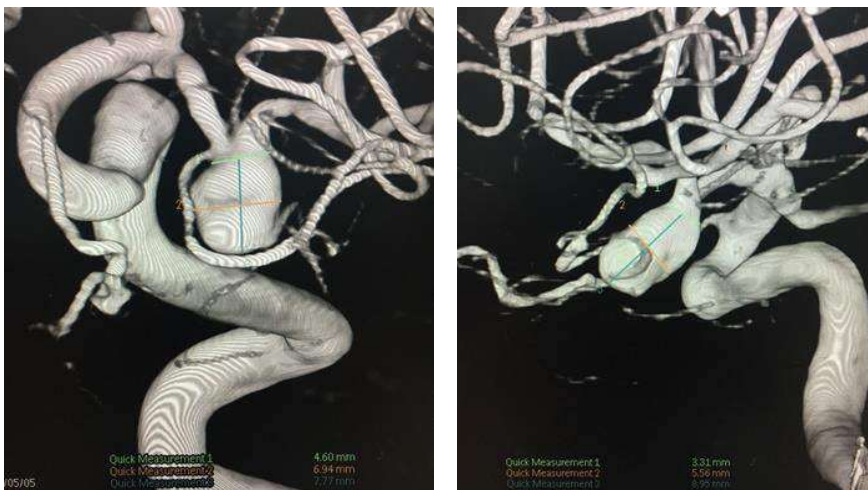

Figure 2. Aneurysm measurement in two orthogonal planes of 3D-DSA images

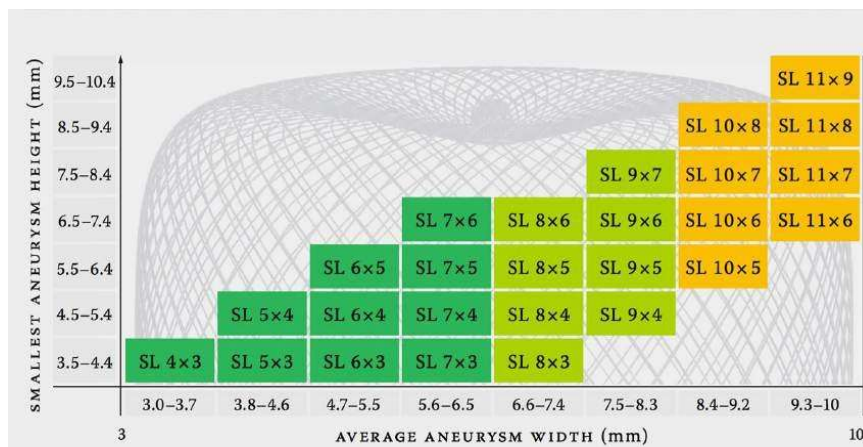


Figure 3. Select the size of the WEB following the manufacturer’s recommendations

Then the WEB was chosen following the oversizing recommendation (1 mm added to the average width and a decrease of 1mm in height) and the manufacturer’s recommendations (Figure 3).

Triaxial access (long introducer sheath, distal access catheter, and VIA microcatheter) was used routinely for the placement of the WEB device (Figure 4A). Post-deployment angiographic runs immediately (Figure 4B) and from 5 to 10 minutes after WEB implantation (Figure 4D) were performed routinely to evaluate for appropriate sizing, lateral compression, and parent artery patency before the WEB detachment.

Clinical and imaging follow-up

The clinical status of patients was evaluated at scheduled visits (1, 3, 6, 12 months, and annual after treatment). Anatomical follow-up was performed by MRI at 3 months post-treatment and DSA after 6 or 12 months was performed in patients with suspicion of major recurrence.

Data collection

A prospective database of all patients with aneurysms treated by WEB device is maintained in the Radiology center of Bach Mai

hospital. The files and follow-up images of all patients were reviewed by investigators. Patient demographics, aneurysm characteristics, and treatment modalities were collected in the picture archiving and communication system (PACS) of Bach Mai hospital.

The primary effectiveness results were evaluated using a modified WEB Occlusion Scale on MRI.⁸

Data analysis

Continuous variables are presented as medians and interquartile ranges (IQR) or mean and standard deviation (SD). Categorical variables are presented as percentages.

Data were processed and analyzed using SPSS software (version 16.0; IBM SPSS Inc, Chicago, IL, USA).

3. Research ethics

The ethical aspects of this research were approved by the Institutional Review Board (IRB) of the National Institute of Health Sciences of Bach Mai Hospital under No.3263/QD-BM on October 23, 2020.

III. RESULTS

From April 2019 to June 2022, 12 patients with 12 aneurysms (9 unruptured and 3 ruptured) were treated with the WEB-SL device.

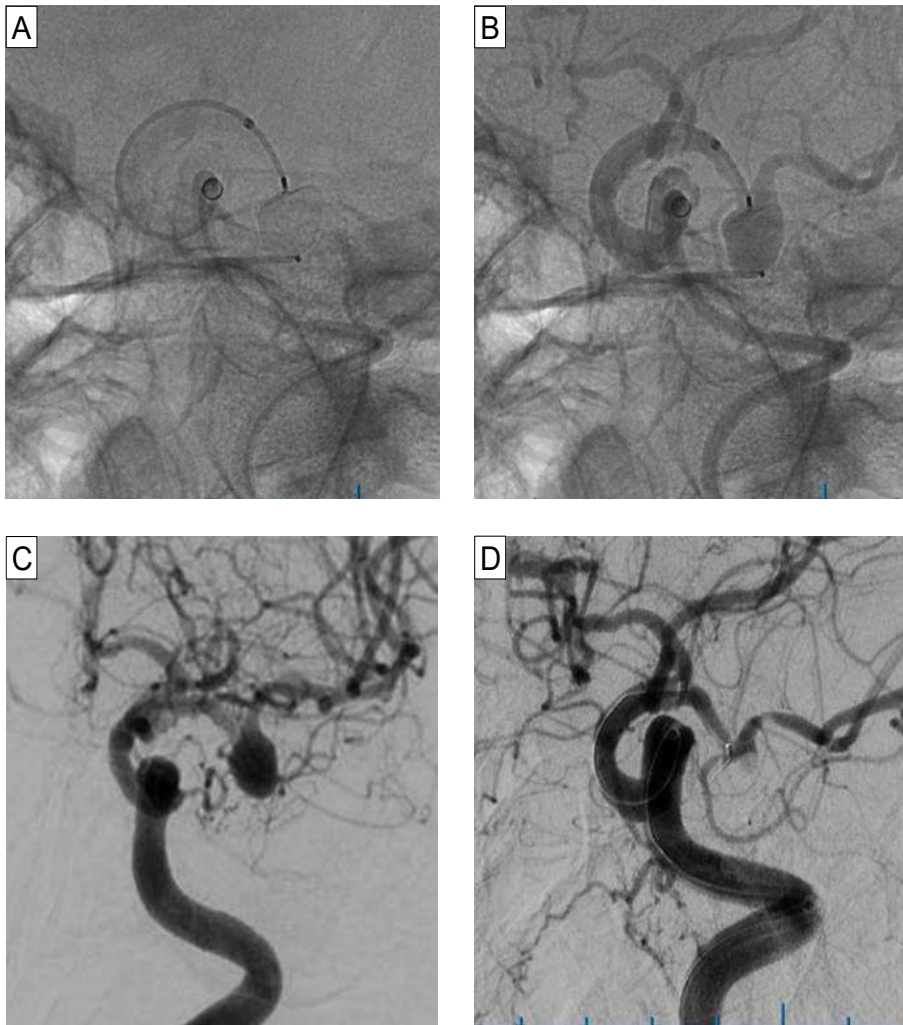


Figure 4. A) Deployment of the WEB inside the aneurysm; B) Post-deployment native digital subtraction angiogram demonstrating the adequate position of the WEB within the aneurysm; C) The wide-necked left MCA aneurysm before treatment; D) Complete occlusion of the aneurysm on angiogram after 10 minutes of WEB implantation

Patient group characteristics

The study group comprised 6 men and 6 women with a median age of 66 years (range, 41-74 years) harboring 12 aneurysms treated with WEB. Among these 12 aneurysms, 9 of these were unruptured and 3 were ruptured. All aneurysms were wide-necked bifurcation aneurysms located at basilar artery apex (BA) (4 aneurysms), anterior communicating artery

(Acom) (4 aneurysms), middle cerebral artery (MCA) (3 aneurysms), and posterior cerebral artery (PCA) (1 aneurysm). The average aneurysm size was 6.3mm (range 4.8 - 8.0mm) with a mean dome to neck ratio of 1.2 ± 0.2 and mean neck size of 5.4mm (range 3.7 - 6.9mm). The aneurysm angle was favorable ($< 45^\circ$) in 10 patients and unfavorable ($> 45^\circ$) in 2 patients. Aneurysm characteristics are shown in detail in Table 1.

Table 1. Aneurysm characteristics, WEB sizing, procedural complications, and outcomes

No	Site	Sac Wid	Sac Heig	Sac Neck	First WEB	Sec WEB	Stroke	SAH comp	mRs dischar
1	BA	5.0	3.0	4.9	6 - 3	0	0	0	0
2	MCA	5.6	5.8	5.9	7 - 3	5 - 2	0	0	0
3	Acom	5.9	6.8	6.9	7 - 4	0	0	0	0
4	Acom	8.0	4.8	5.6	8 - 5	0	0	0	0
5	BA	5.8	4.5	4.3	6 - 3	0	0	0	0
6	MCA	6.5	7.3	4.5	8 - 5	0	1	0	3
7	Acom	7.0	4.7	5.9	8 - 3	0	0	0	0
8	Acom	7.2	6.8	5.3	8 - 5	0	0	0	0
9	MCA	4.8	3.8	3.7	5 - 3	0	0	0	0
10	PCA	5.2	6.2	5.5	6 - 4	0	0	0	0
11	BA	8.0	5.6	6.7	9 - 5	9 - 4	1	0	6
12	BA	6.5	4.6	5.7	7 - 3	0	0	0	0

Note: No, Patient number; BA, basilar artery; MCA, middle cerebral artery; Acom, anterior communicating artery; PCA, posterior cerebral artery; Wid, width in millimeter; Heig, height in millimeter; Sec, second; SAH comp, subarachnoid hemorrhage complication; mRS dischar, modified Rankin Scale at discharge

Antiplatelet treatment

Five out of nine patients with unruptured aneurysms received DAPT with aspirin 81 mg/day and clopidogrel 75 mg/day for 5 days and four patients received DAPT with aspirin 81 mg/day and ticagrelor 90mg x 2/day for 2 days before treatment. Among three patients with a ruptured aneurysm, one patient did not receive any antiplatelet therapy, one patient received aspirin 81mg x 4 for two hours, and one patient received DAPT with aspirin 81mg x 3 and ticagrelor 90mg x 2 for a half-hour before the WEB implantation. After the intervention, among 12 patients, seven patients have been treated with aspirin 81mg daily for four weeks, four patients have been treated with DAPT from one to six months, and one patient was disrupted antiplatelet therapy due to retroperitoneal

hemorrhage.

Procedures

WEB alone was technically successfully deployed and detached in all patients (100%). Among these WEB systems, the WEB 27 system was used in 4 aneurysms, the WEB 21 system was used in 3 aneurysms, and WEB 17 system was used in 5 aneurysms. The appropriate WEB sizing occurred in 10 patients (10/12, 83.33%). Two patients (2/12, 16.67%) needed to use the second WEB device due to the inappropriate of the first WEB.

Primary safety outcomes

No intraoperative subarachnoid hemorrhagic complications occurred in all patients. No spontaneous postprocedural subarachnoid hemorrhages were seen in any patient through

the longest follow-up time of 4 years.

The significant (> 50%) parent artery stenosis was observed in 2 cases (2/12, 16.67%). Thromboembolic complications occurred in two patients (2/12, 16.67%) resulted in major stroke in both cases.

Death occurred in one patient (1/12, 8.3%) due to retroperitoneal hemorrhage and thromboembolic complications. Moderate disability (mRS 3) was observed in 1 patient (1/12, 8.3%) due to major stroke post-intervention. The rest of the patients (10/12, 83.33%) remained clinical intact (mRS 0) at the last follow-up time. Therefore, the procedural success rate was reported in 83.33% of all cases in this study. The safety outcomes are shown in detail in Table 1.

Primary effectiveness outcomes

The mean follow-up time was 19.5 ± 18.5 months (range, 3 months - 50 months).

MRI follow-up at 3 months was obtained in 11 cases with no flow inside the aneurysm in 6 patients (6/11, 54.5%) and a remnant of flow in the aneurysm neck in 5 patients (5/11, 45.5%). These five patients had the residual neck filling which is indicated by the high signal intensity on 3D-TOF of the aneurysm neck extending beyond the expected bounds of the marker recess of the WEB.

Retreatment

Until the last follow-up time, none of the patients was needed to retreat after the WEB procedure.

IV. DISCUSSION

The present study demonstrated that the WEB device alone was feasible to treat appropriately selected ruptured and unruptured wide-necked bifurcation aneurysms with complete occlusion in

54.5 % (6/11), neck remnant in 45.5% (5/11)

and acceptable morbidity (1/12, 8.3%), mortality (1/12, 8.3%).

Comparison with pivotal WEB studies

The success of the technique in our cohort patients (12/12, 100%) was similar to the results of the cumulative population in Europe (WEBCAST, WEBCAST-2, French Observatory) (163/169, 96.4%) and the results of the WEB-IT trial in United State (US) (148/150, 98.67%).^{6,7} There was no difference in periprocedural SAH complications between our study (0%) and pivotal studies in Europe (1.2%), in the US (0%).^{6,7} Moreover, the thromboembolic complications in our study (2/12, 16.67%) were similar to that of studies in Europe (24/167, 14.4%) but higher than that of study in the US (0/150, 0%).^{6,7} Overall, the morbidity and mortality within 30 days post-treatment in our study (morbidity of 8.3%, mortality of 8.3%) was slightly higher compared with these rates reported in the cumulative population in Europe (morbidity of 1.2%, mortality of 0%) and the American population (morbidity of 0.7%, mortality of 0%).^{6,7} Several reasons could be given to explain this difference. Firstly, major stroke rates related to severe parent artery stenosis after WEB implantation in our study (2/12, 16.67%) were higher than in studies in Europe (5/167, 3%) and study in the US (0/150, 0%).^{6,7} Secondly, in our study, no rescue devices such as balloons or stents have been used in case of severe stenosis parent artery but they were used in pivotal WEB studies.^{6,7} And finally, severe retroperitoneal hemorrhage complication occurred in 1 patient of our cohort related to death but was not observed in studies in Europe or US.^{6,7} Regarding primary aneurysm occlusion results, the complete occlusion and neck remnant rates in our study (54.5% and 45.5%) were similar to pivotal studies in Europe (52.9% and 26.1%), in the US (53.8% and

30.8%).^{6,7} This may suggest that the aneurysm occlusion effect of the WEB device is similar in Asian and European, American populations.

Comparison with other treatment methods

It is difficult to compare the variety of endovascular techniques to treat WNBAs due to a variety of aneurysm morphology and the lack of a homogeneous indication system for selecting one or another technique.⁵ Regarding procedural safety, the WEB treatment was related to having a relatively low rate of complications (mortality of 0% and morbidity of 0.7% at 1 month).⁷ About the effectiveness, a recent meta-analysis demonstrated a complete occlusion rate for wide-necked aneurysms (including WNBAs) of only 46% for both surgical and endovascular treatment methods.² Classical coiling alone was reported with 27.1% of complete occlusion in the Maxtrix And Platinum Science trial.⁵ With the stent-assisted coiling, the complete occlusion rate was 45.7%, however, this option was limited to use in case of ruptured aneurysms due to the need of dual antiplatelet therapy.⁵ Balloon-assisted coiling was also the preferred option in case of ruptured aneurysms, but the anatomical results were no real improvement.⁵ Flow diverter stent is a promising treatment, especially for wide-necked side-wall aneurysms but it remains controversial in the treatment of bifurcation aneurysms.⁵

To compare with other treatment options for WNBAs in Vietnam, we searched the thesis database of Hanoi Medical University and Military Medical University. Neither thesis on the endovascular approach nor the surgical approach has been conducted on selected wide-necked bifurcation aneurysm treatment. Only one study has been conducted on all wide-neck aneurysms treated with the endovascular approach by Tran Anh Tuan and Pham Minh Thong (2014).⁹ In this study, 70 aneurysms were

bifurcation aneurysms (42.2%) and the rest was side-wall aneurysms (57.8%).⁹ Most of these aneurysms were ruptured (61.9%) and have been treated by other endovascular techniques including coiling alone, balloon-assisted coiling, stent-assisted coiling, and flow diversion (only in side-wall aneurysms).⁹ Periprocedural SAH complications were reported in 8/155 patients (5.2%) and thromboembolic complications occurred in 12/155 patients (7.7%).⁹ A relative comparison showed that SAH complications were less frequent with WEB treatment but thromboembolic complications appeared to be more frequent than other coiling techniques.⁹ Regarding the occlusion results on MRI post-treatment, a complete occlusion rate was reported in 57/75 aneurysms (76%), and neck remnant rate was reported in 5/75 aneurysms (6.7%), and an aneurysm remnant in 17.3%.⁹ One reason to explain this difference was that the subset of WNBAs typically has lower rates of complete occlusion than side-wall aneurysms.

Technical improvements and prospects in the WEB treatment

From the initial results of this study, we found some difficulties with WEB treatment including WEB sizing and thromboembolic complications due to major branch stenosis. To overcome these difficulties, some suggestions have also been made by the leading experts on WEB treatment in the world.¹⁰ Regarding the WEB sizing, the oversizing method (1-2 mm added to the average width and a decrease of 1-2mm in height) was recommended to reduce the rate of aneurysm recanalization.¹⁰ Moreover, software using artificial intelligence (Sim&Size software) has also been applied to assist in choosing a more suitable WEB size.¹¹ To prevent thromboembolic complications, dual antiplatelet therapy was recommended before the intervention for unruptured aneurysms,

and the use of antiplatelet therapy for ruptured cases was not necessary.¹⁰ Balloon assistance during WEB deployment was used to avoid the protrusion of the WEB into the parent artery. Additionally, C-arm VasoCT should be performed routinely before a detachment of WEB in case of suspicion of severe branch stenosis.

The WEB device is originally designed for WNBAs treatment. However, with the progressive technical improvement of the WEB with lower profiles, smaller sizes, and low-profile catheters, indications are no longer limited to WNBAs treatment but also extended to sidewall aneurysms, aneurysms on distal locations, and narrow neck aneurysms.¹² This device is considered a promising innovative endovascular treatment device.¹²

Limitations

This study has several limitations. First, the number of patients analyzed was relatively small because it was a rare disease and a single-center study, which might affect the reliability of the results. Second, this was a single-arm study, therefore, the effectiveness of the method has not been fully evaluated. Finally, this study was performed based on a retrospective design, so treatment protocols were not heterogeneous before and after the intervention, which might cause difficulties in the interpretation of the study's results.

V. CONCLUSION

The sole WEB system was feasible for both ruptured and unruptured wide-neck bifurcation aneurysms with acceptable safety and good initial efficacy. Some of the difficulties faced during the WEB implantation included WEB sizing and thromboembolic complications due to major branch stenosis. This device is an important alternative tool for the treatment of

wide-neck bifurcation aneurysms, particularly for patients in whom surgical clipping carries high risks and coiling is impossible.

REFERENCES

1. Suarez JI, Tarr RW, Selman WR. Aneurysmal subarachnoid hemorrhage. *New England Journal of Medicine*. 2006;354(4):387-96.
2. Fiorella D, Arthur AS, Chiacchierini R, et al. How safe and effective are existing treatments for wide-necked bifurcation aneurysms? Literature-based objective performance criteria for safety and effectiveness. *Journal of NeuroInterventional Surgery*. 2017;9(12):1197-201.
3. Molyneux A, Kerr R, Yu LM, et al. International Subarachnoid Aneurysm Trial (ISAT) of neurosurgical clipping versus endovascular coiling in 2143 patients with ruptured intracranial aneurysms: A randomized trial. *Journal of stroke and cerebrovascular diseases*. 2002;11(6):304-14.
4. Wiebers DO, Whisnant JP, Huston J III, et al. International Study of Unruptured Intracranial Aneurysms Investigators. Unruptured intracranial aneurysms: natural history, clinical outcome, and risks of surgical and endovascular treatment. *Lancet*. 2003;362:103- 110.
5. Pierot L, Spelle L, Cognard C, et al. Wide neck bifurcation aneurysms: what is the optimal endovascular treatment? *Journal of NeuroInterventional Surgery*. 2021;13(5):e9.
6. Pierot L, Moret J, Barreau X, et al. Safety and efficacy of aneurysm treatment with WEB in the cumulative population of three prospective, multicenter series. *Journal of Neurointerventional surgery*. 2018;10(6):553-9.
7. Arthur AS, Molyneux A, Coon AL, et al. The safety and effectiveness of the Woven EndoBridge (WEB) system for the treatment

of wide-necked bifurcation aneurysms: final 12-month results of the pivotal WEB Intrasaccular Therapy (WEB-IT) Study. *Journal of neurointerventional surgery*. 2019 Sep 1;11(9):924-30.

8. Lubicz B, Klisch J, Gauvrit JY, et al. WEB-DL endovascular treatment of wide-neck bifurcation aneurysms: short- and midterm results in a European study. *AJNR Am J Neuroradiol*. 2014; 35:432–38 10.3174/ajnr.A3869.

9. Tran Anh Tuan, Pham Minh Thong. Study on the treatment of wide-neck cerebral aneurysms by endovascular intervention. PhD thesis of Hanoi Medical University 2014.

10. Goyal N, Hoit D, DiNitto J, et al. How

to WEB: a practical review of methodology for the use of the Woven EndoBridge. *Journal of neurointerventional surgery*. 2020;12(5):512-20.

11. Cagnazzo F, Marnat G, Ferreira I, et al. Comparison of Woven EndoBridge device sizing with conventional measurements and virtual simulation using the Sim&Size software: a multicenter experience. *Journal of NeuroInterventional Surgery*. 2021;13(10):924-9.

12. Van Rooij SB, Sprengers ME, Peluso JP, et al. A systematic review and meta-analysis of Woven EndoBridge single layer for treatment of intracranial aneurysms. *Interventional Neuroradiology*. 2020;26(4):455-60.