

# THE EFFECTS OF KEM CON ONG AND KEM TRI BONG CREAMS ON DOXORUBICIN-INDUCED SKIN ULCER IN RATS

Pham Thi Van Anh<sup>1</sup>, Vu Quang Huy<sup>1</sup>, Nguyen Thi Thanh Loan<sup>1</sup>

Tran Thuy Trang<sup>1</sup>, Nguyen Kim Giang<sup>2</sup>

Nguyen Thi Quynh Nga<sup>3</sup> and Tran Thanh Tung<sup>1,✉</sup>

<sup>1</sup>Hanoi Medical University

<sup>2</sup>Nhat Nhat Pharmaceutical Co.,Ltd

<sup>3</sup>Vietnam University of Traditional Medicine

*The present study evaluated the effects of topical administration of KEM CON ONG and KEM TRI BONG creams on doxorubicin-induced skin ulcer, and their systemic toxicity in ulcerated rats. The skin lesions were induced by a single intradermal injection of 0.2ml doxorubicin 1 mg/0.5ml on the dorsal region. The ulcerated areas were covered topically with dimethyl sulfoxide, KEM CON ONG, or KEM TRI BONG twice a day for 28 days. The results indicated that KEM CON ONG and KEM TRI BONG significantly reduced the ulcer size, increased the hydroxyproline content in animals' skin tissues, and improved the histopathological structure of skin tissues. No significant difference in the healing effect was observed between KEM CON ONG and KEM TRI BONG-treated ulcerated rats. Besides, our study demonstrated that topical administration of KEM CON ONG and KEM TRI BONG creams caused no significant change in the general status, hematological parameters, renal and hepatic functions. Additionally, they did not alter the histology of the liver and kidney in animals. In conclusion, the topical application of KEM CON ONG and KEM TRI BONG creams exerted healing effects on the ulcerated skin and did not cause systemic toxicity in a rat model.*

**Keywords:** Doxorubicin, KEM CON ONG, KEM TRI BONG, skin ulcer, rat.

## I. INTRODUCTION

Skin ulcer is defined as damage of the normal anatomical and functional integrity of the skin. This disease is accompanied with poor blood supply, trauma, infections, diabetes, or connective tissue diseases.<sup>1</sup> To date, dimethyl sulfoxide (DMSO) is perennially one of the most proposed remedies when it comes to treating skin ulceration since it can easily infiltrate into the affected area and scavenge free radicals, which is an important etiology of serious tissue damage.<sup>2</sup> However, for the time being, the

DMSO's availability for clinical use in Vietnam differs from that in the global scale. In addition, the accessibility of DMSO in particular and other effective agents for skin ulcers is still humble. Therefore, there is a rising demand for new agents for the treatment of skin ulcers in healthcare practice with fewer adverse problems and better efficacy.

In these days, the leap of phytotherapy's development has been so notable that the complementary traditional medicine, as one of its aspects, did arouse people's discussion.<sup>3</sup> For centuries, the Vietnamese perennially have had the awareness to utilize folk herbal remedies to cure diseases and illnesses, including skin ulceration precipitated by different reasons. Cream "KEM CON ONG" and "KEM TRI

---

Corresponding author: Tran Thanh Tung

Hanoi Medical University

Email: tranthanhtung@hmu.edu.vn

Received: 07/03/2023

Accepted: 10/04/2023

BONG" consists of a mixture of sesame oil and herbal plants. However, there are no systematic scientific studies to gauge its influence on experimental ulcerated models. Therefore, the present study demonstrated the healing effect of topical administration of KEM CON ONG and KEM TRI BONG creams on doxorubicin-induced skin ulcer in rats, and their systemic toxicity in ulcerated rats.

## II. METHODS

### 1. Preparation of KEM CON ONG and KEM TRI BONG creams

KEM CON ONG and KEM TRI BONG creams were provided by Nhat Nhat Pharmaceutical Co.,Ltd according to the principles of Good Manufacturing Practice, Good Laboratory Practice and Good Storage Practice. KEM CON ONG consists of a mixture of 10% sesame oil and leaves of *Psychotria rubra*, *Camellia sinensis*, *Piper betle*, *Aloe vera*, *Prunus persica*; bark of *Phellodendron amurense*, *Choerospondias axillaris*; roots of *Angelica dahurica*. The ingredients of KEM TRI BONG cream are 2.5% sesame oil and tuber of *Alocasia macrorrhizos*; radix of *Curcuma longa*, walnut oil (*Juglans regia*), honey, camphor (*Cinnamomum camphora*). The expected indication of KEM CON ONG and KEM TRI BONG is to treat ulcerated lesion.

### 2. Experimental animals

Male and female *Wistar* rats (8 - 10 weeks of age and 180 - 220g weight) were used for the study. Rats were housed in the laboratory animal room (25 ± 1°C under 65 ± 5% humidity and 12h dark-light cycle (from 7:00 - 19:00)). Commercial laboratory food and tap water were given *ad libitum*. Rats were kept for one week to acclimatize before starting the experiment.

### 3. Methods

#### ***Evaluation of the healing effect of KEM CON ONG and KEM TRI BONG creams doxorubicin-induced skin ulcer in rats***

The rats were randomly divided into five groups of ten animals as follows:

- Group 1 (normal control rats): received vehicle (sterile distilled water).

- Group 2 (vehicle-treated ulcerated rats): received vehicle (sterile distilled water).

- Group 3 (DMSO-treated ulcerated rats): topically applied DMSO at dose 0.3 g/time, twice a day for 28 days.

- Group 4 (KEM CON ONG-treated ulcerated rats): topically applied KEM CON ONG at dose 0.3 g/time, twice a day for 28 days;

- Group 5 (KEM TRI BONG-treated ulcerated rats): topically applied KEM TRI BONG at dose 0.3 g/time, twice a day for 28 days.

The rats were anesthetized with an intraperitoneal injection of 250 mg/kg chloralhydrate. The dorsal regions of the rats were shaven with an electric shaver and sterilized with 70% alcohol. All animals, except the normal control group, were induced skin ulcer by a single intradermal injection of 0.2ml doxorubicin 1 mg/0.5ml (Doxorubicin Ebewe®, Austria).<sup>4</sup> Then, each animal was placed in a separate cage. Seven days after injection of doxorubicin, the ulcerated areas were covered topically with DMSO, KEM CON ONG, or KEM TRI BONG twice a day for 28 days.

#### *Measurement of size of the ulcer size*

Ulcer sizes were measured at before and after 14 and 28 days of topical administration of test drugs by using a digital camera, with one camera lens and from a constant focal distance. The area of wound was measured in a blind manner using ImageJ Basics software ver 1.38, which were recognized as a software for measuring the area in medical experimental

research by World Health Organization.

*Determination of the hydroxyproline content*

At the end of the experiment, rats were anesthetized with chloral hydrate (250 mg/kg, i.p) and the skin samples were collected from each rat. The concentration of hydroxyproline in the skin was evaluated according to Stegemann H. and Stalder K method.<sup>5</sup>

*Histopathological examinations*

At the end of the experiment, the rats were anesthetized and the ulcerated skin tissue samples were collected for histopathological examinations. The ulcerated skin tissue samples were collected for histopathological examinations. Histopathologic evaluation was carried out randomly in 30% of each group size at Histopathology Department - Military Hospital 103.

**Evaluation of systemic toxicity of topical administration of KEM CON ONG and KEM TRI BONG creams in ulcerated rats**

Blood samples were collected from each rat. The systemic effects were quantified through general conditions, body weight changes of rats; evaluation of hematopoietic function through red blood cell count, hemoglobin, hematocrit, total white blood cells, platelet count; evaluation of liver damage through aspartate aminotransferase level (AST) and alanine aminotransferase level (ALT); evaluation of liver

function through total bilirubin, albumin and total cholesterol; evaluation of kidney function through creatinine level.<sup>6</sup> Follow-up parameters were checked at the time points before applying the test drugs, after 14 days and after 28 days.

At the end of the experiment, rats were euthanized after blood collection and the internal organs (heart, liver, spleen, kidney, and lungs) were removed and observed for any gross lesions. The liver and kidneys of 30 percent of the animals of each group were preserved in 10% buffered formaldehyde solution for histopathological studies. Histopathology studies were performed at the Department of Pathology, Hospital 103.

**Statistical analysis**

SigmaPlot 12.0 (SYSTA Software Inc, Richmond, CA, USA) was used for statistical analysis. Obtained data were expressed as the mean ± SD and analysed by a one-way-ANOVA followed by the post hoc Student-Newman-Keuls test for multiple comparisons. Statistically significant differences were considered when the p value was less than 0.05.

**III. RESULTS**

**1. Healing effects of KEM CON ONG and KEM TRI BONG creams on doxorubicin-induced skin ulcer in rats**

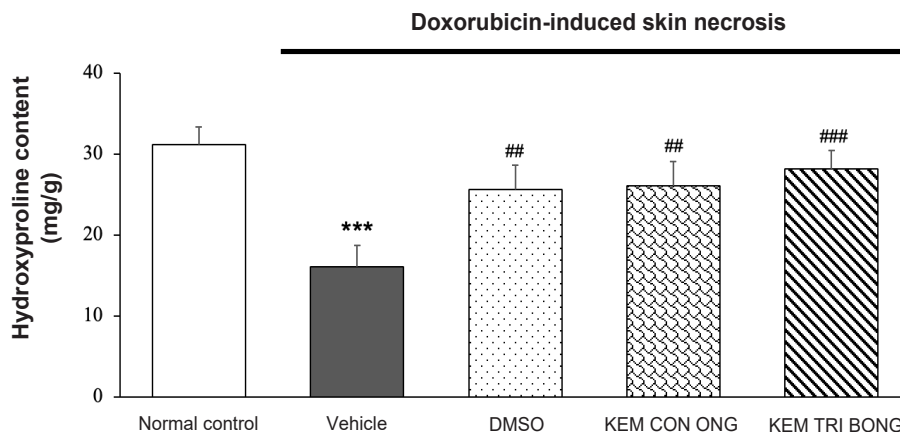
**Table 1. Effects of KEM CON ONG and KEM TRI BONG on ulcer sizes in rats**

Groups	Ulcer sizes (mm <sup>2</sup> )		
	Before of treatment	After 14 days	After 28 days
Vehicle-treated ulcerated rats	43.26 ± 8.64	32.69 ± 7.08	21.43 ± 6.28
DMSO-treated ulcerated rats	40.20 ± 8.81	22.22 ± 6.15 <sup>##</sup>	10.77 ± 3.22 <sup>###</sup>
KEM CON ONG-treated ulcerated rats	39.09 ± 6.52	19.62 ± 6.46 <sup>###</sup>	8.95 ± 2.89 <sup>###</sup>
KEM TRI BONG-treated ulcerated rats	41.14 ± 8.87	19.96 ± 10.81 <sup>##</sup>	8.48 ± 2.94 <sup>###</sup>

<sup>#</sup>p < 0.05, <sup>##</sup>p < 0.01: compared to vehicle-treated ulcerated rats

According to Table 1, the results showed no difference in the areas of skin ulcers between groups ( $p > 0.05$ ) before treatment. After 14 and 28 days of the administration, DMSO, KEM TRI BONG and KEM TRI BONG significantly reduced the ulcer size compared

with the vehicle-treated model group ( $p < 0.01$ ). Additionally, there were no statistical differences in terms of reducing the skin lesions' area between KEM CON ONG and KEM TRI BONG for the time being ( $p > 0.05$ ).



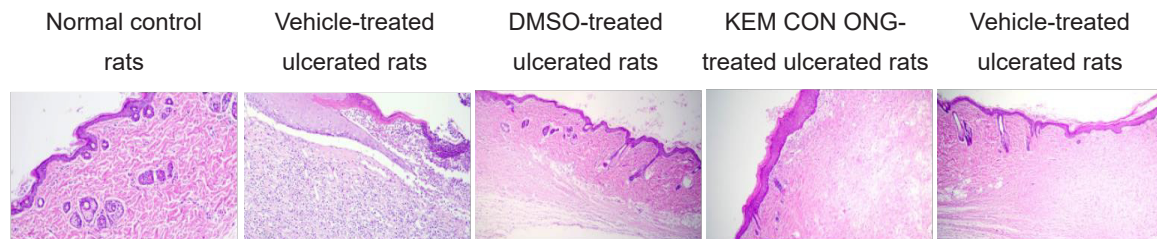
\*\*\* $p < 0.001$  compared to normal control group. ## $p < 0.01$ , ### $p < 0.001$  compared to vehicle-treated ulcerated rats

**Figure 1. Effects of KEM CON ONG and KEM TRI BONG on hydroxyproline content in skin tissues**

As shown in figure 1, the content of hydroxyproline in rat's skin of the vehicle-treated group was significantly lower than the normal control group ( $p < 0.001$ ). Compared with the vehicle-treated model group, treatment of DMSO, KEM TRI BONG and KEM TRI BONG

significantly increased the hydroxyproline content in the skin tissue. In addition, there were no significant differences in the effects of KEM CON ONG and KEM TRI BONG on the concentration of hydroxyproline in rat skin ( $p > 0.05$ ).

**2. The microscopic representative images of skin ulcer in Wistar rats**



**Image 1. The microscopic representative images of skin ulcer in Wistar rats**

The skin biopsy of the normal control rat demonstrates the proper stratum epidermis with keratinization, clear basal lamina, skin-dependent components in the dermis layer,

loose connective tissue and small blood vessels. Skin structure is normal. In the vehicle-treated ulcerated rats, the skin tissue showed a large necrosis area and the surface was

covered with necrotic substances, erythrocyte, fibrin, many inflammatory cells, neutrophils and macrophages. On the 28<sup>th</sup> day, DMSO, KEM CON ONG and KEM TRI BONG improved the histopathological structure of skin tissues, which demonstrated the slight growth of dermal papillae and epidermal ridges.

**3. Evaluation of systemic toxicity of topical administration of KEM CON ONG and KEM**

**TRI BONG creams in ulcerated rats**

**General status**

During the experimental period, there was an increase in body weight in each group of animals. No significant difference was seen as compared to that of the control group. None of the animals in all treated groups showed any macroscopic or gross pathological changes when compared to the control group.

**Effect on hematopoietic function**

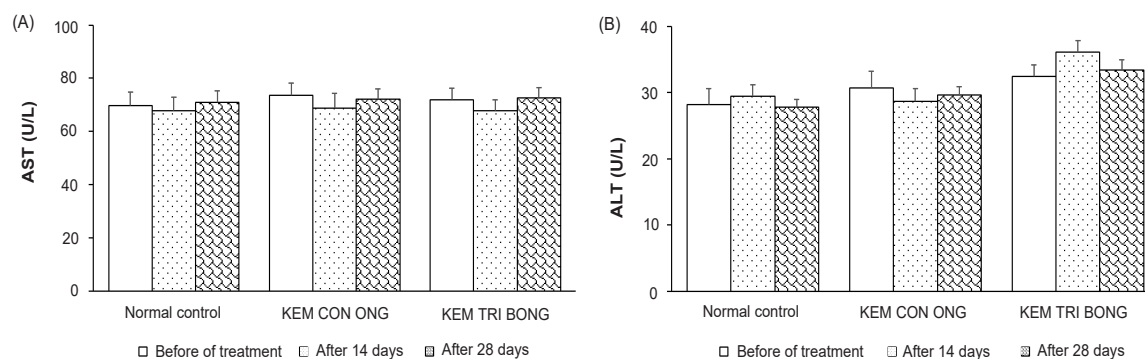
**Table 2. Effect of KEM CON ONG and KEM TRI BONG on hematopoietic function**

Parameters	Groups	Before of treatment	After 14 days	After 28 days
RBC (T/L)	Normal control	8.46 ± 0.71	8.98 ± 1.25	8.82 ± 1.05
	KEM CON ONG	8.30 ± 1.36	8.06 ± 1.05	8.59 ± 1.20
	KEM TRI BONG	8.73 ± 0.87	8.63 ± 0.72	9.03 ± 1.19
Hemoglobin (g/dl)	Normal control	11.74 ± 0.95	11.64 ± 1.42	11.15 ± 1.14
	KEM CON ONG	11.26 ± 1.20	11.18 ± 0.78	11.06 ± 0.84
	KEM TRI BONG	11.48 ± 1.11	11.25 ± 0.99	11.91 ± 1.27
Hematocrit (%)	Normal control	46.19 ± 3.30	46.30 ± 6.38	44.30 ± 5.24
	KEM CON ONG	44.06 ± 5.54	42.08 ± 3.97	42.97 ± 4.88
	KEM TRI BONG	43.57 ± 3.44	43.22 ± 4.52	46.06 ± 5.36
Mean Corpuscular Volume (fl)	Normal control	52.70 ± 2.21	51.90 ± 2.08	51.50 ± 2.07
	KEM CON ONG	52.10 ± 2.81	50.60 ± 1.90	51.00 ± 1.89
	KEM TRI BONG	51.80 ± 1.87	51.10 ± 1.20	50.90 ± 1.29
White blood cell (G/l)	Normal control	6.20 ± 1.46	5.45 ± 1.58	6.29 ± 1.21
	KEM CON ONG	6.29 ± 1.29	5.07 ± 1.39	7.61 ± 1.74
	KEM TRI BONG	5.91 ± 1.62	5.37 ± 0.98	6.81 ± 1.82
Platelets (G/l)	Normal control	615.30 ± 84.03	584.10 ± 75.85	624.80 ± 99.65
	KEM CON ONG	602.60 ± 86.28	578.30 ± 81.62	633.00 ± 83.56
	KEM TRI BONG	546.80 ± 96.51	556.90 ± 80.29	562.00 ± 86.57

As shown in Table 2, there were no significant difference in red blood cells count, hematocrit, hemoglobin level, white blood cell and platelet

count between KEM CON ONG and KEM TRI BONG-treated groups and normal control group (p > 0.05).

**Effect on liver damage**



**Figure 2. Effect of KEM CON ONG and KEM TRI BONG on AST and ALT level**

Figure 2 demonstrates that KEM CON ONG and KEM TRI BONG did not cause statistical difference in AST and ALT level when comparing

the treated groups to the normal control group ( $p > 0.05$ ).

**Effect on liver function**

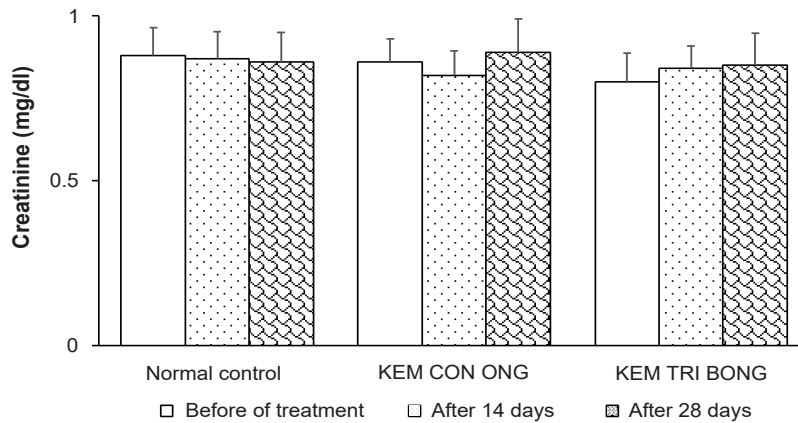
**Table 3. Effect of KEM CON ONG and KEM TRI BONG on liver function**

Groups		Before of treatment	After 14 days	After 28 days
Total bilirubin (mmol/L)	Normal control	9.90 ± 0.82	9.56 ± 1.12	10.31 ± 0.62
	KEM CON ONG	9.69 ± 0.79	9.76 ± 1.14	10.13 ± 0.72
	KEM TRI BONG	9.86 ± 0.83	10.10 ± 1.04	10.37 ± 0.81
Albumin (g/dL)	Normal control	2.62 ± 0.15	2.43 ± 0.33	2.57 ± 0.28
	KEM CON ONG	2.69 ± 0.19	2.50 ± 0.35	2.62 ± 0.23
	KEM TRI BONG	2.65 ± 0.27	2.46 ± 0.21	2.60 ± 0.24
Total cholesterol (mmol/L)	Normal control	1.34 ± 0.17	1.26 ± 0.22	1.36 ± 0.18
	KEM CON ONG	1.47 ± 0.12	1.32 ± 0.22	1.38 ± 0.21
	KEM TRI BONG	1.45 ± 0.12	1.36 ± 0.15	1.41 ± 0.20

The effect of KEM CON ONG and KEM TRI BONG on the total bilirubin, albumin and total cholesterol of the normal control group and treated groups are presented in Table 3. No statistical difference was observed between groups ( $p > 0.05$ ).

**Effect on kidney function**

Figure 3 demonstrates that topical treatment of KEM CON ONG and KEM TRI BONG did not cause statistical difference in creatinine levels when comparing the treated groups to the normal control group ( $p > 0.05$ ).

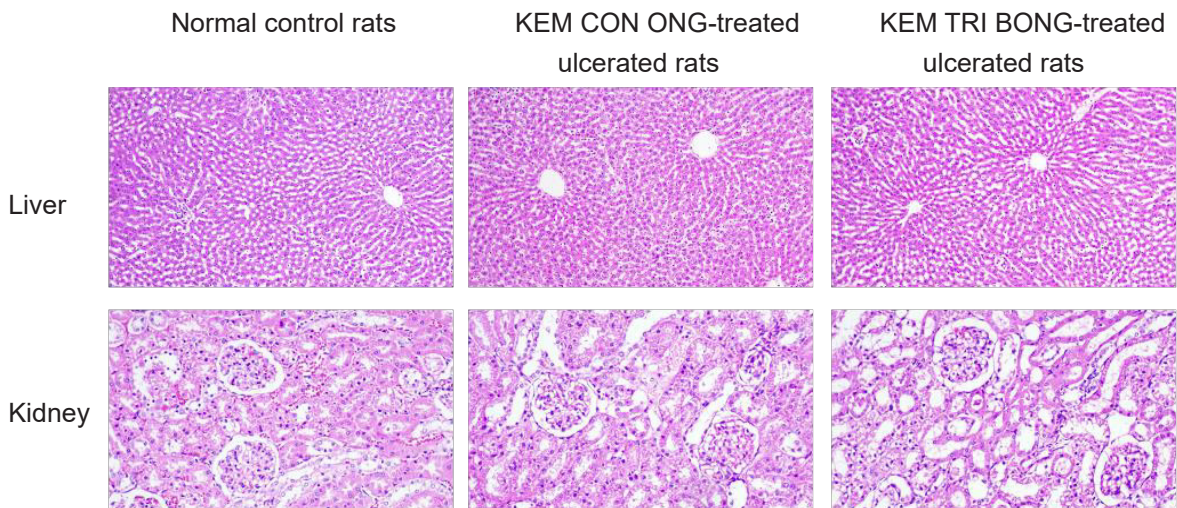


**Figure 3. Effect of KEM CON ONG and KEM TRI BONG on creatinine level**

***Histopathological examination***

No gross lesions or changes in size were observed when subjected all experimental rats to a full gross necropsy which examined the hearts, livers, lungs, kidneys and abdominal

cavities. There were no significant differences in histopathological examinations of livers and kidneys between KEM CON ONG and KEM TRI BONG-treated ulcerated rats and normal control rats.



**Image 2. Histopathological examinations of livers and kidneys**

**IV. DISCUSSION**

In this study, we evaluated the effect of topical administration of cream KEM CON ONG and KEM TRI BONG on wounds induced by doxorubicin in rats. KEM CON ONG and KEM TRI BONG significantly reduced the size of the wounded area, increased the hydroxyproline content in animals' skin tissues, and improved

the histopathological structure of skin tissues. In this experiment, doxorubicin was used as a skin ulcerative agent. Doxorubicin could affect the replication and translation process, as well as activate the gene which is responsible for cellular apoptosis. Eventually, the ulcer exerted by doxorubicin injection are deemed to be

broad and deep, indicating that the ulceration model triggered by doxorubicin is adequately reliable to gauge the efficiency of test drugs. In order to alleviate the triggered skin lesion, the newly formed radicals in the cytosol and interstitial space should be withdrawn by potent antioxidants for clinical practice. This is why DMSO was used as positive control in this experiment.<sup>7</sup>

Cream KEM CON ONG and KEM TRI BONG consists of a mixture of sesame oil and some herbal plants. There was no previous research in terms of assessing the efficacy of combing these agents together in, which means the effectiveness of this combination is the first experimental study relating to this issue. We realized that the gained result regarding ameliorating the ulcers of the two test drugs could be due to the healing abilities of each components forming these creams. Some herbal plants of KEM CON ONG cream have been reported the healing effect in ulcerated skin. *Angelica dahurica* extract possesses multiple effects in the treatment of skin lesions, including anti-inflammatory activity, antimicrobial activity, cell stimulation properties, and the promotion of wound healing.<sup>8</sup> According to Le Thi Lien and Arif Budiman, *Piper betle* leaf extract could accelerate the healing of incision wounds in male rats by stimulating the NIH3T3 fibroblast proliferation and increasing the hydroxyproline content in the skin lesion. Thus, *Piper betle* can be used as an ingredient in developing natural-origin drugs for the treatment of cutaneous wounds.<sup>9,10</sup> Moreover, some ingredients of KEM TRI BONG also exhibited potent wound-healing capacity. *Curcuma longa* extract was efficient in accelerating cutaneous wound repair through modulation of the inflammatory process and stimulus of re-epithelization by an Akt/mTOR-dependent mechanism.<sup>11</sup> Walnut oil promoted

healing of wounds and skin injury repair in rats via regulating the NF- $\kappa$ B pathway.<sup>12</sup> In addition, honey, prevents wound infections and promoted wound healing through its natural antimicrobial properties and by acting as a physical barrier to the wound site.<sup>13</sup> Sesame, one of the components of test drugs, has been studied for its effects on wounds. Sesame oil may accelerate ulcerated lesion healing by shortening the inflammation phase and promoting the proliferation phase.<sup>14</sup> So, KEM CON ONG and KEM TRI BONG contain ingredients that have healing effect on the ulcerated skin. The two creams have a common ingredient which is sesame oil but in different concentration. We figure out that KEM TRI BONG cream with 2.5% of sesame oil seemed to result in a better outcome.

In addition, we also evaluated the systemic toxicity of topical administration of KEM CON ONG and KEM TRI BONG creams on ulcers in rats. Long-term topical application can also affect systemic effects, especially applied on open wounds. Overall, the findings of this study indicated that topical administration of KEM CON ONG and KEM TRI BONG creams caused no significant change in the general status, hematological parameters, renal and hepatic functions. Additionally, they did not alter the histology of the liver and kidney in animals.

## V. CONCLUSION

The present study demonstrated that the topical application of KEM CON ONG and KEM TRI BONG creams exerted healing effects on the ulcerated skin on doxorubicin-induced skin ulcer in rats, and did not cause systemic toxicity in a rat model. No significant difference in the healing effect was observed between KEM CON ONG and KEM TRI BONG-treated ulcerated rats.

## REFERENCES

1. Jiaojiao Zhong, Yu Lan, Shuying Fu, et



- al. Botulinum toxin a injection for treatment of chronic skin ulcer: A case series and literature review. *The international journal of lower extremity wounds*. 2019;18(1):97-103.
2. Ludwid CU, Stoll HR, Obristl R, et al. Prevention of cytotoxic drug induced skin ulcers with dimethyl sulfoxide (DMSO) and  $\alpha$ -tocopherole. *European Journal of Cancer and Clinical Oncology*. 1987;23(3):327-329.
3. World Health Organization. *Guidelines for Assessing Quality of Herbal Medicines With Reference to Contaminants and Residues*. World Health Organization, Geneva 2007.
4. Vural Kesik, Bulent Kurt, Turan Tunc, et al. Melatonin ameliorates doxorubicin-induced skin necrosis in rats. *Annals of Plastic Surgery*. 2011;65(2):250-253.
5. H Stegemann, K Stalder. Determination of hydroxyproline. *Clinica Chimica Acta*. 1967;18(2):267-73.
6. Organisation for Economic Co-operation and Development. *Guidelines for the testing of chemicals repeated dose oral toxicity study in rodents*, Environmental Health and Safety Monograph Series on Testing and Assessment No 407. 2008.
7. Box VGS. The intercalation of DNA double helices with doxorubicin and nogalamycin. *The journal of molecular graphics and modelling*. 2007;26(1):14-19.
8. Wan-Ting Yang, Chun-Yen Ke, Wen-Tien Wu, et al. Effects of *Angelica dahurica* and *Rheum officinale* extracts on excisional wound healing in rats. *Evidence-Based Complementary and Alternative Medicine*. 2017:1583031.
9. Le Thi Lien, Nguyen Thi Tho, Do Minh Ha, et al. Influence of phytochemicals in piper betle linn leaf extract on wound healing. *Burns & Trauma*. 2015;3:23.
10. Arif Budiman, Risris Khoerunnisa, Tazyinul Qoriah A. Wound-healing test of *Piper Betle* leaf extract and *Aloe Vera* in gel preparation. *International journal of applied pharmaceutics*. 2018;10(3):1-6.
11. Chris K Danilevicz, Vivian P Wagner, Nilson Ferreira, et al. Curcuma longa L. Effects on Akt/mTOR Pathway and NF- $\kappa$ B Expression During Skin Wound Healing: An Immunohistochemical Study. *Applied Immunohistochemistry & Molecular Morphology*. 2021;29(10):e92-e100.
12. Qiang Ma, Yin-Sheng Wu, Jiang-Yong Shen, et al. Walnut oil promotes healing of wounds and skin defects in rats via regulating the NF- $\kappa$ B pathway. *Pharmazie*. 2018;73(12):721-724.
13. Joel Yupanqui Mieles, Paulo Bartolo, Cian Vyas, et al. Honey: An advanced antimicrobial and wound healing biomaterial for tissue engineering applications. *Pharmaceutics*. 2022;14:1663.
14. Seyed Mahdi Tabatabaei, Ayat Mohebi Far, Zahra Saremi, et al. The effect of sesame oil and cucurbita on healing wounds caused by third-degree burn. *Journal of Skin and Stem Cell*. 2017;4(3-4):e68333.