

CONSERVATIVE MANAGEMENT OF CHYLOUS FISTULA FOLLOWING LAPAROSCOPIC PARTIAL NEPHRECTOMY FOR RENAL CELL CARCINOMA: A CASE REPORT AND LITERATURE REVIEW

Nguyen Dao Uyen¹, Nguyen Huy Hoang¹, Do Truong Thanh¹ and Le Van Hung^{2,✉}

¹Department of Urologic Surgery, VietDuc University Hospital

²Center of Gastroenterology – Hepatology - Urology, Vinmec International Hospital

Chylous fistula is a rare complication following renal surgery, especially partial nephrectomy due to renal cell cancer. A unified treatment guideline for this complication is currently unavailable. We report a clinical case of chylous fistula after laparoscopic partial nephrectomy due to renal cell cancer, seen on the 4th postoperative day (POD), which was successfully treated conservatively by octreotide and diet adjustments. We take this opportunity to review similar cases mentioned in the literature in order to contribute to the knowledge of symptoms, management and treatment of this complication.

Keywords: Chylous fistula, chylous leak, complications, laproscopic partial nephrectomy.

I. INTRODUCTION

Chylous fistula defined as the accumulation of lipid-rich lymph in cavities of the body mostly resulted from damages to the lymphatic channels during surgery. This type of complication increases both the length of hospital stay and financial burden for patients.¹

The rate of chylous fistula following laparoscopic nephrectomy is approximately 5.2%.² Since the percentage of kidney-related postoperative chylous leak is extremely low, there is not yet a unified management guideline for this complication. Most physicians take conservative management as the first-line treatment, then proceed with surgical intervention when the conservation work failed.³

Most of the cases reported in the literature are of chylous fistula after total nephrectomy due to cancer, or removal of kidney(s) in a

kidney transplant; however, there was few recorded cases of chylous fistula after partial nephrectomy.

Therefore, we report a clinical case of chylous fistula after laparoscopic retroperitoneal partial nephrectomy due to renal cell carcinoma which was successfully treated conservatively.

II. CASE PRESENTATION

A 38-year-old male patient with normal medical history presented to the urology clinic for routine health check, was found to have a right kidney tumor by ultrasound. The patient denied back pain and hematuria. His clinical examination had unremarkable findings. His complete blood count, liver functions, kidney functions and electrolytes were within normal ranges. Computed tomography (CT) scan confirmed a tumor in the right kidney measuring 18*16 mm with well-defined margins, poor enhancement upon contrast injection (Figure 1), resulting in slight protrusion of the renal capsule but no surrounding infection, no renal calyx nor

Corresponding author: Le Van Hung

Vinmec International Hospital

Email: le.hung@live.com

Received: 22/06/2023

Accepted: 24/07/2023

renal pelvis invasion. The patient was biopsied under ultrasound guidance with the pathological result of renal cell carcinoma. The preoperative

diagnosis was renal cell carcinoma of the right kidney, stage cT1aN0M0.

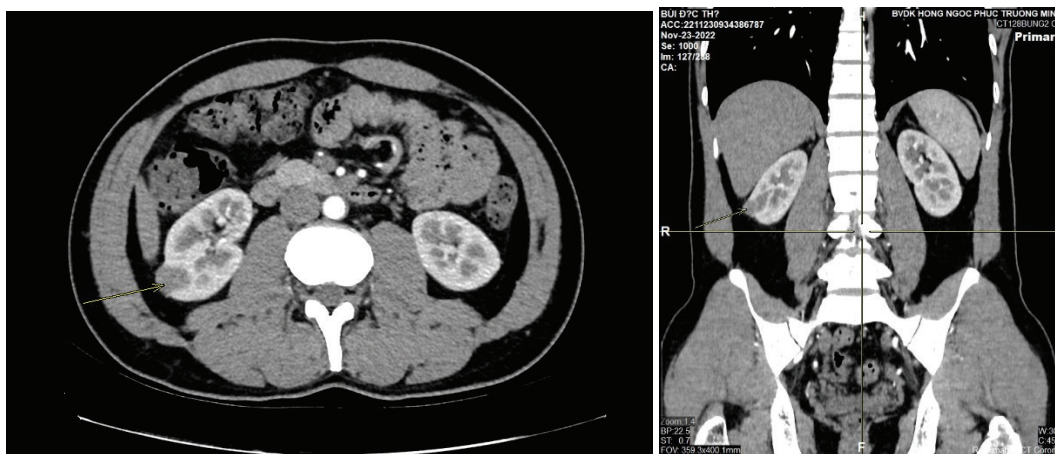


Figure 1. Image of a tumor on the right side

The patient underwent laparoscopic retroperitoneal partial nephrectomy without lymph node dissection. In the process of renal peduncle exposure for vascular control, a small node measured roughly 5 mm was dissected and removed. The renal tumor was then excised and taken out through a small opening of the trocar entry. No lymphatic leakage was detected intraoperatively, and a small drainage tube was inserted into the surgical field. The post-operative pathological results were similar to those of pre-operative biopsies with the histopathological type being chromophobe. The lymph node removed showed the absence of malignant cells.

The patient had a smooth post-op recovery with normal oral intake immediately after the surgery. Patient 's condition was stable on

PODs and had dilute pinkish output drainage which the amount gradually decreased over time. On POD 4, his drainage output appeared milky whitish (150 ml/day) which showed characteristics of triglyceride-elevated chyle on biochemical analysis. Soon after, the patient started a low salt, low fat, and high protein diet, and also received subcutaneous injections of octreotide at 0.1 mcg twice a day. The opalescent drainage was reduced the next day to roughly 50 ml/day. Drain was removed on POD 7 and patient was discharged on POD 9 (Figure 2). Octreotide was only administered up to the time of hospital discharge. the patient was instructed to follow a low-fat diet for 2 weeks. At 3 months follow up, the patient denied any symptom, and resonance imaging gave good results.

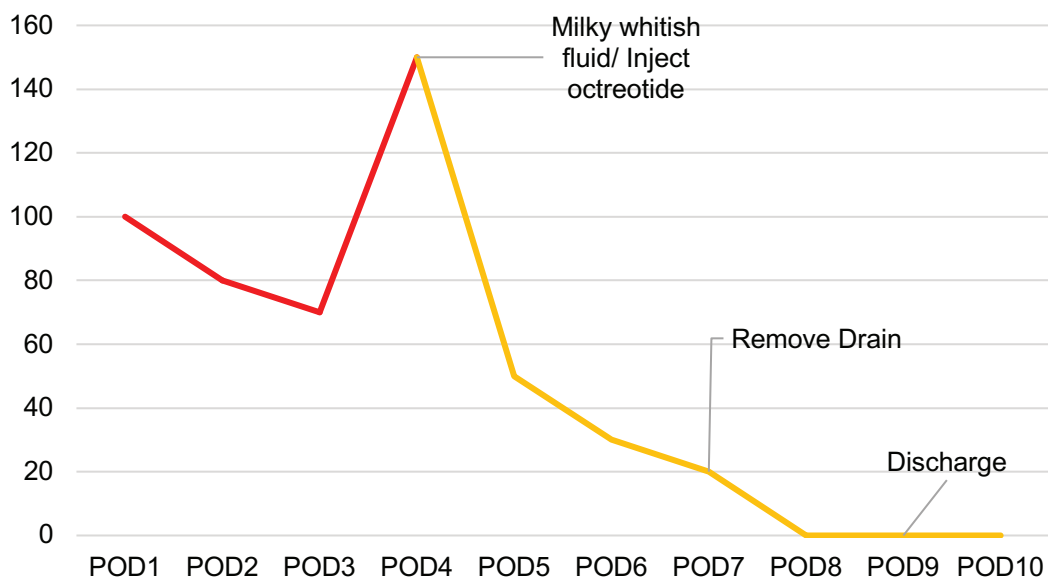


Figure 2. Drainage output per day (ml)

III. DISCUSSION

Chylous fistula rate following renal surgery and causal hypothesis

The incidence of postoperative chylous fistula involving the kidney has been reported to be approximately 5.2% and is commonly associated with total nephrectomy because of the extensive surgical procedure and often accompanied by peduncular node dissection. Chylous fistula is also more common in patients undergoing renal removal for transplantations since they require extensive dissection to obtain the longest possible renal arteries and veins. Meanwhile, simple nephrectomy without lymph node dissection, and partial nephrectomy, had a lower rate of chylous fistula, perhaps due to a smaller dissection field. Putting these two groups of patients in comparison, Kim et al showed that in patients with partial nephrectomy, the leakage rate was only about 2.6%, which was less when compared to the percentage of total nephrectomy and renal transplantation groups (6%).² In our patient, although it was a partial nephrectomy, we had a lymph node dissection

in the access to the renal peduncle, which could be the cause of the lymphatic leak.

Laparoscopic surgeries also play a role in increasing the risk of postoperative chylous fistula. The study of Tiong HY et al showed that the rate of chylous fistula caused by open surgeries for kidney removal in transplantations was 0.6% which is lower compared with 2% for laparoscopic removal.⁴ Some hypotheses suggested that bipolar or energy knives used to dissect the renal pedicle during laparoscopic surgery rises the risk of chylous fistula.⁵

Symptoms of fistula usually present - from POD 4,⁶ but they can appear immediately,⁷ or within a few weeks or months,⁶ after surgery. The clinical presentation of chylous fistula varies between patients with or without drainage. In patients holding drainage, a milky white output may be seen via the drain, whereas in patients without drainage, symptoms may include abdominal distention, vomiting, nausea, and possibly cloudy white discharge oozing through previous surgical scar.² The diagnosis of chylous

fistula is usually not clinically difficult, and it can be confirmed by biochemical testing of the draining or residual fluid with characteristic of a milky white fluid, amounting ≥ 100 ml per day with triglyceride content ≥ 110 mg/dl.¹

Chylous fistula management

Because this issue is so uncommon, there is currently no clear treatment protocol. Most authors agree that conservative treatment should be undertaken first, with intervention occurring only when conservative treatment fails.^{3,8,9}

Conservative management, with success rate ranging from 67% to 100%^{8,9} is often the preferred option. It aims to reduce the lymphatic flow through the mesentery, restore nutrient loss, and alleviate symptoms.

Dietary change, including a diet of high protein, low fat and salt, is the first-line and simplest treatment. Changing diet only can resolve up to 50% of mild chylous fistula cases. This diet should be maintained for up to several months to prevent recurrence of chylous fistula.⁹

Some authors recommend parenteral nutrition right at the time a chylous fistula is diagnosed.² However, in our opinion, it is unnecessary to receive intravenous nutrition as long as the patient consumed enough calories. The complete parenteral nutrition should only be done in cases of poor physical condition, or malabsorption.

When dietary modification applied as a management for a period of time cannot show effectiveness, octreotide (a compound with similar effects to somatostatin) can be considered. The exact mechanism of octreotide to manage chylous leak is unclear; the probable explanation is it reduces fat absorption in the small intestine wall, thereby reducing lymphatic flow thus lessening lymphatic leakage.¹⁰

We recommend starting octreotide as soon as possible, as dietary adjustments usually take several weeks to about 2 months for the fistula to close. Prolonged lymphatic leakage can result in nutritional and immunological disorders, which have potentials to delay the patient's postoperative recovery, and increase the psychological burden due to prolonged hospital stay. Doses of octreotide can be started at 100 ug/day and can go up to 200 ug depending on patient response.³ Usually after 24-72 hours, octreotide will decrease lymph flow, then lymphatic leakage can be improved as a result.⁹ In this case, we used a dose of 200 ug at the time of diagnosis, and the patient responded to treatment only 24 hours afterwards.

Regarding the duration of octreotide use, Jairath et al recommend using octreotide for up to 2 weeks, counted from responses to treatment noted.³ In our patient's case, due to the small amount of fluid leaking through the drainage, and the unavailability of oral octreotide, we ended octreotide at the time of patient discharge, yet the low lipid diet still remained.

Surgical intervention is indicated for patients unresponsive to conservative therapies, but the timing of intervention is controversial. Jairath et al recommend that primary surgery should be performed in patients with lymphatic leaks greater than 1000 ml/day for more than 48 hours because of the potential for poor response to conservative treatment.³ In other cases, some authors agree that intervention should be performed only after 4 weeks of conservative treatment failure, while some authors recommend that it is possible to wait up to 12 weeks after conservative treatment.² The goal of surgery is to control all the lymphatic vessels in the renal peduncle and its surroundings with

clipping devices. Laparoscopic surgeries should be preferred because it is less invasive and can provide a better field to detect the lymphatic leak site. Foods high in lipids such as avocado can be given to patients 6 hours prior to surgery because they can increase the rate of detecting the leak site during dissection.³

IV. CONCLUSION

Postoperative chylous fistula, although uncommon, is a serious complication after laparoscopic surgery for kidney diseases, requiring early diagnosis and management to prevent serious consequences for patients. Conservative management is always the first priority, and octreotide plays an important role in treatment. It is highly recommended that octreotide be administered as soon as possible after a chylous fistula has occurred. To prevent this complication, surgical dissection and control of peri-peduncle fatty tissue by clipping are required, and a renal fossa drainage should be placed for monitoring patients at risk for this complication.

REFERENCES

1. Singh H, Pandit N, Krishnamurthy G, Gupta R, Verma GR, Singh R. Management of chylous ascites following pancreaticobiliary surgery. *JGH Open*. 2019; 3(5): 425-428. doi:10.1002/JGH3.12179
2. Kim BS, Yoo ES, Kim TH, Kwon TG. Chylous Ascites as a Complication of Laparoscopic Nephrectomy. *J Urol*. 2010; 184(2): 570-574. doi:10.1016/J.JURO.2010.03.128.
3. Jairath A, Singh A, Ganpule A, Mishra S, Sabnis R, Desai M. Management Protocol for Chylous Ascites After Laparoscopic Nephrectomy. *Urology*. 2015; 86(3): 521-528. doi:10.1016/J.UROLOGY.2015.06.001.
4. Tiong HY ee, Goel RK, White WM, Goldfarb DA, Kaouk JH. Chylous ascites after laparoscopic donor nephrectomy. *Asian J Endosc Surg*. 2015; 8(1): 34-39. doi:10.1111/ASES.12144.
5. Kim BS, Kwon TG. Chylous ascites in laparoscopic renal surgery: Where do we stand? *World J Clin Urol*. 2016; 5(1): 37-44. doi:10.5410/WJCU.V5.I1.37.
6. Lv S, Wang Q, Zhao W, et al. A review of the postoperative lymphatic leakage. *Oncotarget*. 2017; 8(40): 69062. doi:10.18632/ONCOTARGET.17297.
7. Ferrandière M, Hazouard E, Guicheteau V, et al. Chylous ascites following radical nephrectomy: efficiency of octreotide as treatment of a ruptured thoracic duct. *Intensive Care Med*. 2000; 26(4): 484-485. doi:10.1007/S001340051190.
8. Harper JD, Breda A, Leppert JT, Veale JL, Gritsch HA, Schulam PG. Experience With 750 Consecutive Laparoscopic Donor Nephrectomies—Is it Time to Use a Standardized Classification of Complications? *J Urol*. 2010; 183(5): 1941-1946. doi:10.1016/J.JURO.2010.01.021.
9. LEIBOVITCH I, MOR Y, GOLOMB J, RAMON J. The diagnosis and management of postoperative chylous ascites. *J Urol*. 2002; 167(2 Pt 1): 449-457. doi:10.1016/S0022-5347(01)69064-5.
10. Leibovitch I, Mor Y, Golomb J, Ramon J. Chylous ascites after radical nephrectomy and inferior vena cava thrombectomy. Successful conservative management with somatostatin analogue. *Eur Urol*. 2002; 41(2): 220-222. doi:10.1016/S0302-2838(01)00034-3.