

# CLINICAL OUTCOMES OF MODIFIED WIDMAN FLAP SURGERY WITH AND WITHOUT ADJUNCTIVE EMDOGAIN IN ANTERIOR MAXILLARY PERIODONTITIS: RANDOMIZED SPLIT-MOUTH CLINICAL TRIAL

Dinh Thi Thuy<sup>1</sup>, Tran Van Dung<sup>2</sup>  
Phan Thi Bay<sup>3</sup> and Do Thi Thao<sup>1,✉</sup>

<sup>1</sup>Can Tho University of Medicine and Pharmacy

<sup>2</sup>Ho Chi Minh City Odonto-Stomatology Hospital

<sup>3</sup>My Nha Dental Clinic, Ho Chi Minh City

*Modified Widman flap is a well-established surgical treatment for advanced periodontitis. However, its regenerative potential remains limited, prompting the adjunctive use of Emdogain to improve clinical outcomes. This randomized split-mouth clinical trial evaluated the adjunctive use of Emdogain in anterior maxillary periodontitis at Ho Chi Minh City Odonto-Stomatology Hospital from July 2025 to March 2026. A total of 34 patients with 128 maxillary anterior teeth were included, with comparable baseline probing pocket depth (PPD) and clinical attachment level (CAL) between groups. At 1 month, both parameters were significantly reduced in the Emdogain group ( $p < 0.001$ ). At 3 months, Emdogain achieved greater mean PPD ( $3.68 \pm 0.64$  mm vs  $4.52 \pm 0.72$  mm) and CAL ( $4.08 \pm 0.68$  mm vs  $4.52 \pm 0.72$  mm), with  $p < 0.001$ . Pocket closure was more frequent in the Emdogain group at both 1 and 3 months. Plaque index (PI) and gingival index (GI) improved significantly in both groups without significant between-group differences. Pain on day 7 was lower in the Emdogain group, and the proportion of good outcomes at 3 months was higher (76.2% vs 52.4%,  $p = 0.020$ ). In conclusion, adjunctive Emdogain provided additional some clinical benefits when used in conjunction with modified Widman flap surgery in patients with anterior maxillary periodontitis in short-term.*

**Keywords:** Periodontitis, modified Widman flap, Emdogain, periodontal regeneration.

## I. INTRODUCTION

Periodontitis is a chronic inflammatory disease of the tooth-supporting tissues and a leading cause of tooth loss in adults. It progresses insidiously, gradually destroying the alveolar bone and clinical attachment level, thereby significantly affecting function and aesthetics. In Vietnam, periodontitis remains prevalent, with many cases diagnosed at advanced stages.<sup>1</sup>

In cases with deep periodontal pockets, flap surgery is a key approach to remove inflamed tissue and control infection.<sup>2</sup> However, contemporary periodontal therapy increasingly emphasizes not only inflammation control but also regeneration of lost periodontal structures. Enamel matrix derivative (EMD), commercially available as Emdogain, has been shown to promote the regeneration of cementum, periodontal ligament, and alveolar bone by mimicking physiological periodontal development.<sup>3</sup> Previous research have reported that the adjunctive use of EMD in periodontal surgery may improve clinical attachment level

---

Corresponding author: Do Thi Thao

Can Tho University of Medicine and Pharmacy

Email: dtthao@ctump.edu.vn

Received: 08/04/2026

Accepted: 28/04/2026

and reduce probing pocket depth compared with surgery alone. Nevertheless, the magnitude and consistency of these benefits remain variable across studies, particularly depending on baseline defect characteristics, anatomical location, and study design. In addition, evidence focusing specifically on anterior maxillary sites and short-term healing outcomes remains limited, especially in studies employing a split-mouth design that can better control inter-individual variability.<sup>4,5,6,7,8</sup> Therefore, this study aimed to evaluate the short-term clinical outcomes of modified Widman flap surgery with and without adjunctive EMD in anterior maxillary periodontitis using a split-mouth design with a 3-month follow-up.

## II. MATERIAL AND METHODS

### 1. Study subjects

Patients diagnosed with periodontitis were examined, treated, and followed up at Ho Chi Minh City Odonto-Stomatology Hospital from July 2025 to March 2026.

Eligible participants were aged 18 to 45 years, provided informed consent, and were diagnosed with stage II periodontitis or higher according to the 2017 classification. Inclusion criteria comprised clinical attachment loss (CAL)  $\geq 3$  mm, alveolar bone loss  $\geq 15\%$  of root length or  $\geq 3$  mm on radiographs, and probing pocket depth (PPD)  $\geq 5$  mm at at least one site. All patients had received non-surgical periodontal therapy at least 4 weeks prior to surgery. Symmetrical periodontal lesions were required in the maxillary anterior segments (teeth 11-13 and 21-23), with at least one site per side presenting PPD  $\geq 5$  mm with bleeding on probing and an indication for flap surgery. Each patient had a minimum of 16 natural teeth, including at least 4 teeth in each maxillary quadrant, excluding third

molars. Study teeth were free of caries, pulpal pathology, or restorations interfering with measurements, with no horizontal mobility  $> 1$  mm, no vertical mobility, and no occlusal trauma. Exclusion criteria included pregnancy or lactation, systemic conditions contraindicating periodontal surgery such as uncontrolled diabetes, severe cardiovascular disease, hematologic disorders, use of anticoagulants, history of organ transplantation, or severe neurological disorders. Patients undergoing or having received head and neck radiotherapy, currently receiving orthodontic treatment, or having used antibiotics or anti-inflammatory drugs for more than 10 days within the past 3 months were also excluded. Additional exclusions were smoking  $\geq 10$  cigarettes per day for over 10 years, oral fungal infections, extensive caries, poor compliance, or failure to complete the 3-month follow-up.

### 2. Methods

#### Study design and sampling

This was a randomized controlled clinical trial with a split-mouth design. Patients were consecutively recruited using convenience sampling during the study period. The sample size was calculated using the formula for comparing two independent means  $n = 2$  with  $ES = .$  In this formula,  $n$  represents the minimum sample size required for each group,  $\mu_1$  and  $\mu_2$  are the mean changes in probing pocket depth after treatment in the intervention and control groups, respectively, and  $\sigma$  is the standard deviation of the control group. With a significance level of 95% ( $\alpha = 0,05$ ) and a study power of 80% ( $\beta = 0,2$ )  $\rightarrow z = 1,96$  và  $\beta = 0,842$ . Based on the study by Dong Thi Mai Huong (2020), the parameters used were  $\mu_1 = 4.42$  mm,  $\mu_2 = 3.35$  mm, and  $\sigma = 1.75$ .<sup>6</sup> Accordingly, the minimum required sample size was 43 teeth per group. Given the split-mouth design,

each patient served as their own control. A total of 34 eligible patients were included, each presenting with symmetrical periodontitis lesions in the maxillary anterior region (teeth 11-13 and 21-23), with a minimum of 2 and a maximum of 6 affected symmetrical teeth (one to three teeth per side). In total, 128 teeth were analyzed, corresponding to 64 teeth per group. Within each patient, one maxillary side was

randomly assigned to modified Widman flap surgery with adjunctive Emdogain, while the contralateral side received flap surgery alone. Split-mouth allocation was performed using a computer-generated random number sequence by independent researcher not involved in clinical measurements. The treatment side was assigned prior to the intervention.

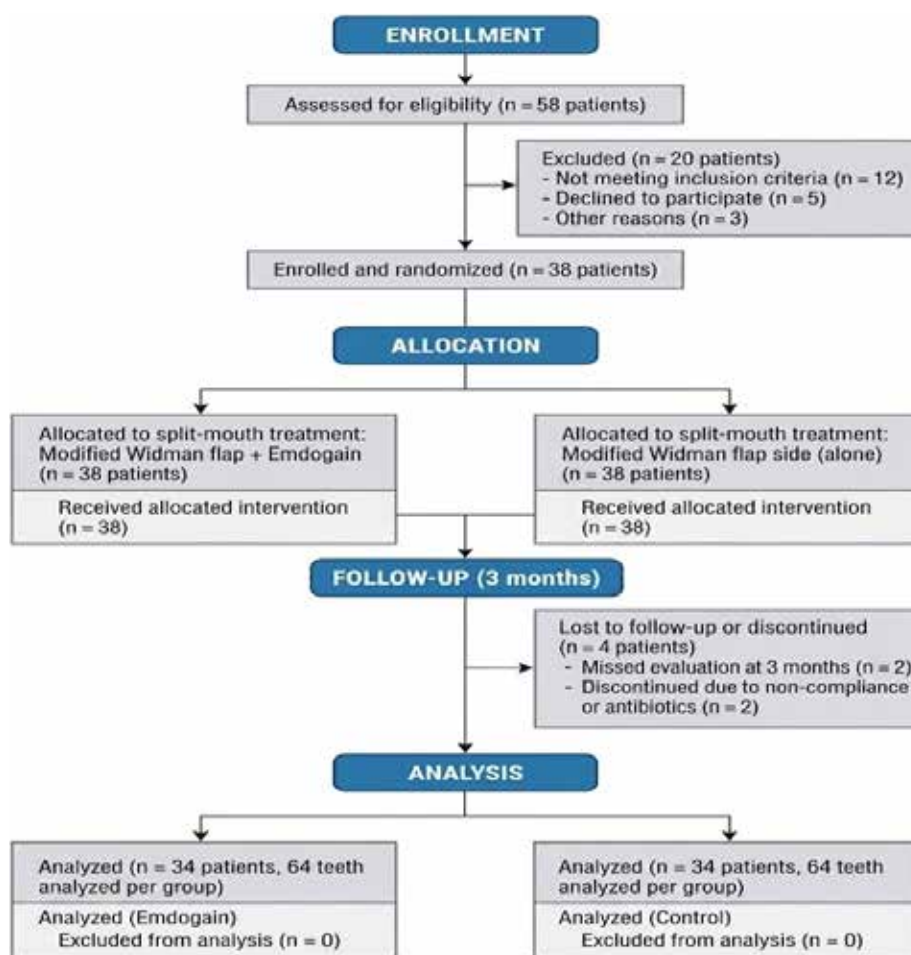


Figure 1. Flow diagram of participant selection and follow-up

**Study variables and outcomes:**

- Baseline characteristics included age (mean ± SD and categorized into 18-25, 26-35, and 36-45 years old) and gender (male, female). The independent variable was treatment modality (modified Widman flap with

or without Emdogain).

- Primary outcomes were PPD and CAL, measured using a Williams probe at six sites per tooth (mm) at baseline, 1 month, and 3 months. Changes were calculated relative to baseline.

- Secondary outcomes included plaque index (PI) and gingival index (GI) (Löe and Silness), pocket status after treatment (Serino classification: closed 1-3 mm, moderate 4-5 mm, deep  $\geq$  6 mm), and postoperative pain assessed by VAS immediately and at day 7.

- Overall treatment outcomes at 3 months were categorized as good, fair, or poor based on improvements in PI, GI, PPD reduction, and CAL gain.

### **Periodontal treatment protocol**

All patients received phase I therapy including full-mouth scaling, root planing, and oral hygiene instruction until  $PI \leq 1$  prior to surgery. Surgery followed a split-mouth design. Clinical parameters were recorded preoperatively. After local anesthesia, a modified Widman flap with three incisions and full-thickness flap reflection was performed. Granulation tissue was removed, and root surfaces were debrided and planed using Gracey curettes and ultrasonic scalers, followed by saline irrigation and conditioning with 24% EDTA for 2 minutes. In the test sites, Emdogain® gel was applied to the root surface before flap closure, no Emdogain was used in control sites. Flaps were sutured and protected with a periodontal dressing. Postoperatively, patients received Amoxicillin 500 mg, Paracetamol 500 mg, and Medrol 16 mg. Sutures were removed after 2 weeks, and patients were followed up periodically according to the hospital protocol.

### **Data processing and analysis**

Collected data were cleaned, coded, and analyzed using Microsoft Excel and SPSS software (version 25.0). In descriptive statistics, qualitative variables (PPD, CAL, PI, GI, and VAS pain scores) were presented as mean  $\pm$

standard deviation, while categorical variables (pocket closure rate and treatment outcome classification) were expressed as frequencies and percentages. For analytical statistics, comparisons between the two treatment conditions within the same patient were performed using paired analyses. The Paired Samples t-test was used for normally distributed continuous variables. For qualitative variables, the McNemar test was used to compare paired binary outcomes (pocket closure rate), whereas the Wilcoxon signed-rank test was applied for paired ordinal categorical outcomes (treatment outcome classification). A p-value  $< 0.05$  was considered statistically significant.

### **3. Ethics in research**

The study protocol was approved by the Institutional Review Board of Can Tho University of Medicine and Pharmacy (Approval No. 25.542.HV/PCT-HĐĐĐ, dated June 30, 2025). All procedures complied with established ethical guidelines in biomedical research, with full protection of participants' rights and well-being.

## **III. RESULTS**

This study included 34 patients with periodontitis treated at Ho Chi Minh City Odonto-Stomatology Hospital from July 2025 to January 2026. Among them, 12 patients had 2 symmetrical affected teeth, 14 had 4 teeth, and 8 had 6 teeth, yielding a total of 128 maxillary teeth included in the analysis. The mean age was  $37.8 \pm 6.5$  years old. The 36-45 years old age group accounted for the highest proportion (50.0%), followed by 26-35 years old (32.4%) and 18-years old (17.6%). Females comprised 58.8% and males 41.2%.

**Table 1. Changes in PPD and CAL between groups before and after treatment**

Parameter	Time point	Emdogain group (n = 64)	Control group (n = 64)	p-value*
PPD (mm)	Baseline	6.52 ± 0.73	6.47 ± 0.76	0.715
	After 1 month	4.21 ± 0.68	4.89 ± 0.74	< 0.001
	After 3 months	3.68 ± 0.64	4.52 ± 0.72	< 0.001
CAL (mm)	Baseline	6.81 ± 0.79	6.76 ± 0.82	0.630
	After 1 month	4.45 ± 0.71	5.12 ± 0.77	< 0.001
	After 3 months	4.08 ± 0.68	4.94 ± 0.75	< 0.001

*\*Paired Samples t-test*

At 1 month, PPD in the Emdogain group decreased to 4.21 ± 0.68 mm compared with 4.89 ± 0.74 mm in the control group (p < 0.001), corresponding CAL values were 4.45 ± 0.71 mm and 5.12 ± 0.77 mm (p < 0.001). At 3 months,

further improvement was observed, with PPD reaching 3.68 ± 0.64 mm versus 4.52 ± 0.72 mm, and CAL 4.08 ± 0.68 mm versus 4.94 ± 0.75 mm in the Emdogain and control groups, respectively (p < 0.001).

**Table 2. Changes in PI and GI between groups before and after treatment**

Parameter	Time point	Emdogain group (n = 64)	Control group (n = 64)	p-value*
PI	Baseline	1.78 ± 0.41	1.75 ± 0.44	0.805
	After 1 month	0.62 ± 0.28	0.66 ± 0.31	0.312
	After 3 months	0.54 ± 0.26	0.58 ± 0.27	0.285
GI	Baseline	1.82 ± 0.38	1.80 ± 0.40	0.826
	After 1 month	0.70 ± 0.30	0.73 ± 0.32	0.415
	After 3 months	0.61 ± 0.28	0.65 ± 0.29	0.280

*\*Paired Samples t-test*

PI and GI decreased significantly in both groups at 1 month, with no intergroup differences and continued to improve at 3 months without significant differences between groups (p > 0.05).

**Table 3. Pocket closure rate and VAS pain scores after surgery**

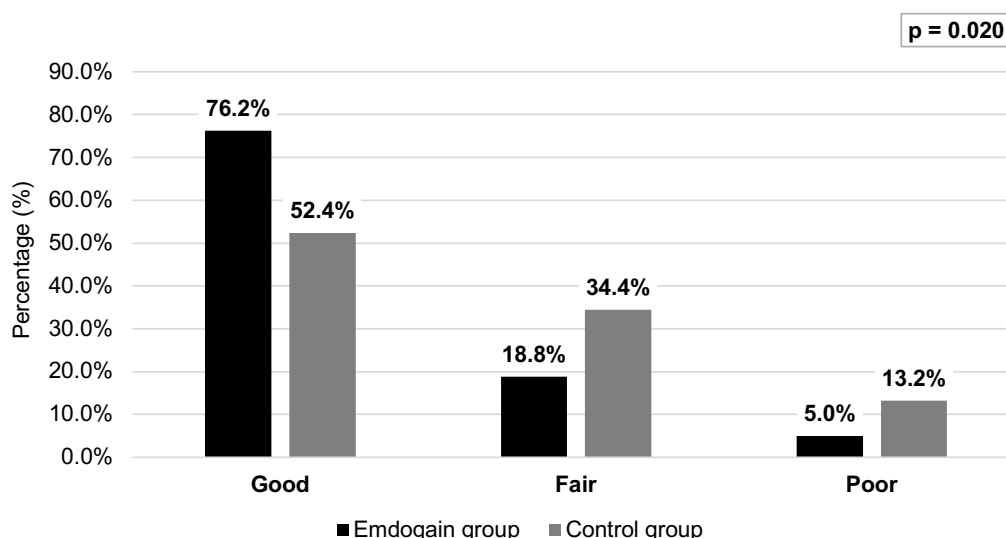
Parameter	Time point	Emdogain group (n = 64)	Control group (n = 64)	p-value*
Pocket closure	After 1 month	28 (43.8%)	15 (23.4%)	0.028 <sup>a</sup>
	After 3 months	40 (61.9%)	24 (38.1%)	0.021 <sup>a</sup>

Parameter	Time point	Emdogain group (n = 64)	Control group (n = 64)	p-value*
VAS	Postoperatively	2.36 ± 0.88	2.42 ± 0.91	0.702 <sup>b</sup>
	After 7 days	1.02 ± 0.71	1.46 ± 0.83	0.025 <sup>b</sup>

<sup>a</sup>McNemar test, <sup>b</sup>Paired Samples t-test

The proportion of pocket closure was significantly higher in the Emdogain group at 1 month (43.8% vs. 23.4%, p = 0.028) and 3 months (61.9% vs. 38.1%, p = 0.021). VAS pain scores were similar immediately postoperatively

(p = 0.674) but lower in the Emdogain group at day 7 (1.02 ± 0.71 vs. 1.46 ± 0.83, p = 0.025). No serious adverse event was observed during the follow-up period.



**Figure 2. Overall treatment outcome at 3 months**

Wilcoxon signed-rank test

At 3 months, the proportion of “good” outcomes was significantly higher in the Emdogain group (76.2% vs. 52.4%), while the proportion of “poor” outcomes was lower (5.0% vs. 13.2 %), the difference was statistically significant (p = 0.020).

#### IV. DISCUSSION

The present study has demonstrated that adjunctive use of Emdogain with modified Widman flap surgery provides significant clinical benefits compared with surgery alone. Specifically, greater improvements in PPD and

CAL were observed in the Emdogain group. At 3 months, mean PPD was 3.68 ± 0.64 mm in the Emdogain group and 4.52 ± 0.72 mm in the control group, while CAL gain was 4.08 ± 0.68 mm versus 4.52 ± 0.72 mm, respectively (p < 0.001). The proportion of pocket closure was also significantly higher in the Emdogain group from 1 month and sustained at 3 months (61.9% vs. 38.1%, p = 0.041). Consequently, the overall rate of “good” treatment outcomes at 3 months was significantly greater with adjunctive Emdogain (76.2% vs. 52.4%, p = 0.038).

In this study, greater reductions in PPD and gains in CAL were observed in the Emdogain

group compared with flap surgery alone after 3 months of follow-up. These findings are consistent with previous evidence, earlier studies also demonstrated greater PPD reduction (approximately 2.7 mm) and CAL gain (> 1.5 mm) in the Emdogain group after 1 year.<sup>9</sup> Compared with these reports, our results show substantial short-term regenerative effects within 3 months. A systematic review and meta-analysis by Fidan et al. (2024) confirmed that the addition of enamel matrix derivatives to surgical procedures significantly enhances CAL gain and overall clinical outcomes compared to control procedures without Emdogain.<sup>4</sup> Another systematic review of 79 trials (2020) reported that Emdogain improved CAL by approximately 1.27 mm compared with open flap surgery alone after  $\geq 12$  months of follow-up.<sup>5</sup> Domestic studies support similar trends. Nguyen Thi Hong Minh et al. (2022) reported a reduction in PPD from  $7.30 \pm 1.48$  mm to  $4.02 \pm 0.62$  mm and a CAL gain of  $3.37 \pm 1.48$  mm after 12 months ( $p < 0.001$ ).<sup>7</sup> Dong Thi Mai Huong (2020) found greater PPD reduction ( $4.42 \pm 1.87$  mm vs.  $3.35 \pm 1.75$  mm) and CAL gain ( $3.47 \pm 1.92$  mm vs.  $2.84 \pm 2.37$  mm) in the Emdogain group ( $p < 0.05$ ).<sup>6</sup> Similarly, Nguyen Thi Thanh Ngoc (2021) reported significantly better improvements in PPD and CAL with Emdogain at 3 and 6 months in a split-mouth design.<sup>8</sup> Notably, PI and GI decreased similarly in both groups ( $p > 0.05$ ), indicating that plaque control and gingival inflammation are primarily influenced by phase I therapy and patient compliance, whereas the added benefit of Emdogain is more evident in regenerative parameters such as CAL and PPD. Long-term studies suggest that attachment gains achieved with Emdogain may remain stable for 5-10 years with appropriate supportive care,<sup>10</sup> implying that our short-term results may have lasting clinical relevance. However, the relatively short follow-

up period and the lack of stratification by defect morphology are important limitations.

Mechanistically, Emdogain is an enamel matrix derivative rich in amelogenins, which promotes periodontal ligament cell differentiation, stimulates new cementum formation, and re-establishes the physiological attachment apparatus. It also modulates inflammation, enhances growth factor expression, and supports early angiogenesis, thereby improving wound healing and clot stability.<sup>3</sup> The robust biological mechanism comprehensively explains our clinical findings. First, it accounts for the higher early pocket closure rate at 1 month. Second, it explains the significantly lower VAS scores at day 7, this reduction in early postoperative pain and swelling is further supported by a recent clinical trial.<sup>11,12</sup> Consequently, these favorable early healing events may translate into a significantly higher proportion of good overall treatment outcomes at 3 months in our study. This result is consistent with robust clinical evidence, notably the randomized controlled trial by Cortellini et al. (2011), in which the adjunctive use of Emdogain during flap surgery resulted in significantly greater improvements in PPD and CAL, alongside higher overall clinical success rates, compared to flap surgery alone.<sup>13</sup> Furthermore, a meta-analysis by Nibali et al. (2020) comparing regenerative surgery with access flap procedures also showed that biologic agents such as Emdogain increase pocket closure and successful attachment gain.<sup>5</sup> Importantly, no adverse events such as infection, abnormal tissue reactions, or tooth loss were observed in either treatment group during the follow-up period. This is consistent with previous studies reporting a favorable safety profile of both conventional flap surgery and adjunctive Emdogain. Okuda et al. (1999) also reported no adverse tissue reactions,

infections, or delayed healing with Emdogain use.<sup>14</sup> Similarly, McGuire et al. (2003) reported that common postoperative events, including pain, swelling, bleeding, bruising, and sensitivity, were comparable between test and control sites, although control sites tended to present with greater severity of these symptoms. Notably, patient-reported discomfort was significantly lower in the Emdogain group, with faster resolution over time.<sup>12</sup> This is in line with our result of lower pain scores in the Emdogain group at day 7. However, our findings should be interpreted with caution given the relatively short follow-up period.

Overall, these findings are consistent with prior evidence. Specifically, the higher and sustained rate of pocket closure in the test group supports the role of Emdogain as an effective regenerative adjunct in the treatment of periodontitis with bony defects. This study also adds clinical data from a Vietnamese population, suggesting that these benefits are reproducible in routine practice. A key strength of the current study is the split-mouth design, which reduces inter-individual variability and allows for more reliable comparisons within the same patient. However, several limitations should be considered. First, while no serious adverse events, such as infections, abnormal tissue reactions, or tooth loss, were recorded during the study, potential confounding factors were not extensively evaluated. Second, the follow-up period of 3 months is relatively short for assessing long-term stability, although it remains appropriate and valuable for evaluating early clinical responses to the intervention. Third, while we acknowledge that baseline defect characteristics (initial pocket depth, defect morphology) likely play a crucial role in treatment outcomes, our study was not originally designed to perform subgroup

analyses to identify which specific case profiles achieve optimal results. Further studies with longer follow-up periods, comprehensive evaluation of potential confounders, and more detailed stratification based on initial defect characteristics are needed to confirm these findings.

## V. CONCLUSION

Modified Widman flap surgery with adjunctive Emdogain provides better short-term clinical outcomes compared with flap surgery alone in the treatment of anterior maxillary periodontitis. The Emdogain group demonstrated significantly greater PPD reduction, CAL gain, and higher rates of pocket closure after 3 months of follow-up. Gingival inflammation control was comparable between groups, while the Emdogain group showed a trend toward earlier postoperative pain reduction. Within the limits of the present study, these findings suggest that Emdogain may be a beneficial adjunctive therapy in periodontal treatment. However, further studies with longer follow-up are needed to confirm its long-term effectiveness.

## REFERENCES

1. GBD 2016 Disease and Injury Incidence and Prevalence Collaborators. Global, regional, and national incidence, prevalence, and years lived with disability for 328 diseases and injuries for 195 countries, 1990-2016: a systematic analysis for the Global Burden of Disease Study 2016. *Lancet*. 2017, 390(10100): 1211-1259. doi: 10.1016/S0140-6736(17)32154-2.
2. Varshney SKR, Siddharth M. Effects of low-level diode laser therapy as an adjunct to modified Widman flap in subjects with stage III periodontitis: a clinical study. *SRM J Res Dent Sci*. 2024, 15(4): 182-190. doi: 10.4103/srmjfds.srmjfds\_22\_24.

3. Kulakauskienė R, Aukštakalnis R, Šadzevičienė R. Enamel matrix derivate induces periodontal regeneration by activating growth factors: a review. *Stomatologija*. 2020, 22(2): 49-53.
4. Fidan I, Labreuche J, Huck O, Agossa K. Combination of enamel matrix derivatives with bone graft vs bone graft alone in the treatment of periodontal intrabony and furcation defects: a systematic review and meta-analysis. *Oral Health Prev Dent*. 2024, 22: 655-664. doi: 10.3290/j.ohpd.b5871494.
5. Nibali L, Koidou VP, Nieri M, Barbato L, Pagliaro U, Cairo F. Regenerative surgery versus access flap for the treatment of intra-bony periodontal defects: a systematic review and meta-analysis. *J Clin Periodontol*. 2020, 47 Suppl 22:320-351. doi: 10.1111/jcpe.13237.
6. Dong Thi Mai Huong. Clinical outcome post surgery for treatment of chronic periodotal with enamel matrix derivatives - Emdogain. *J Med Res*. 2020, 132(8): 46-54. doi: 10.52852/tcncyh.v132i8.1568 .
7. Nguyen Thi Hong Minh, Dong Thi Mai Huong, Nguyen Thi Phuong Tra. Result of periodontal regeneration using Emdogain. *Vietnam Med J*. 2022, 515(2): 39-42. doi: 10.51298/vmj.v515i2.2751.
8. Nguyen Thi Thanh Ngoc, Nguyen Thu Thuy, Pham Anh Vu Thuy. Clinical efficacy of enamel matrix derivative in treatment of periodontal intra-bony defects. *VNUHCM J Health Sci*. 2021, 2(2): 155-161. doi: 10.32508/stdjhs.v2i2.462.
9. Froum SJ, Weinberg MA, Rosenberg E, Tarnow D. A comparative study utilizing open flap debridement with and without enamel matrix derivative in the treatment of periodontal intrabony defects: a 12-month re-entry study. *J Periodontol*. 2001, 72(1): 25-34. doi: 10.1902/jop.2001.72.1.25.
10. De Ry SP, Rocuzzo A, Lang NP, Sculean A, Salvi GE. Long-term clinical outcomes of periodontal regeneration with enamel matrix derivative: A retrospective cohort study with a mean follow-up of 10 years. *J Periodontol*. 2022, 93(4): 548-559. doi: 10.1002/JPER.21-0347.
11. Lee JH, Kim DH, Jeong SN. Adjunctive use of enamel matrix derivatives to porcine-derived xenograft for the treatment of one-wall intrabony defects: two-year longitudinal results of a randomized controlled clinical trial. *J Periodontol*. 2020, 91(7): 880-889. doi: 10.1002/JPER.19-0432.
12. McGuire MK, Nunn M. Evaluation of human recession defects treated with coronally advanced flaps and either enamel matrix derivative or connective tissue. Part 1: Comparison of clinical parameters. *J Periodontol*. 2003, 74(8): 1110-1125. doi: 10.1902/jop.2003.74.8.1110.
13. Cortellini P, Tonetti MS. Clinical and radiographic outcomes of the modified minimally invasive surgical technique with and without regenerative materials: a randomized-controlled trial in intra-bony defects. *J Clin Periodontol*. 2011; 38(4): 365-373. doi: 10.1111/j.1600-051X.2011.01705.x.
14. Okuda K, Momose M, Miyazaki A, et al. Enamel matrix derivative in the treatment of human intrabony osseous defects. *J Periodontol*. 2000, 71(12): 1821-1828. doi: 10.1902/jop.2000.71.12.1821.