

SUBCUTANEOUS IMMUNOGLOBULIN THERAPY SHORTENS CORTICOSTEROID USE IN CHILDREN WITH DERMATOMYOSITIS: A CASE REPORT

Luong Thi Lien¹, Mai Thanh Cong², Nguyen Ngoc Quynh Le¹, Le Huyen Trang¹
Hoang Ngoc Thach¹, Phan Van Nha² and Nguyen Thi Dieu Thuy^{2,✉}

¹National Children's Hospital

²Hanoi Medical University

Dermatomyositis (DM) is a rare autoimmune disease characterized by symmetric proximal muscle weakness and skin rashes. Corticosteroids and methotrexate are mainly prescribed to treat dermatomyositis based on the consensus of experts. Intravenous immunoglobulin is used in severe cases to reduce the dose and duration of corticosteroid therapy, the number of flare-up periods, thereby reducing complications and sequelae. Subcutaneous immunoglobulin has advantages over intravenous immunoglobulin because it can be used at home and maintains stable blood gammaglobulin levels. We report a case of a 2-years old child with early-onset dermatomyositis treated with subcutaneous immunoglobulin. The child's condition improved, and corticosteroids were discontinued after 18 months of treatment. We prove that subcutaneous immunoglobulin therapy can shorten the duration of corticosteroid therapy in children with dermatomyositis.

Keywords: Dermatomyositis, juvenile dermatomyositis, subcutaneous immunoglobulin.

I. INTRODUCTION

Dermatomyositis (DM) is the most common autoimmune myopathies in children, with an incidence of 3.2/1 million children per year, usually with onset between 4 - 14 years of age.¹ The disease is one of the many idiopathic inflammatory myopathies with cutaneous involvement (predominately affects the skin and muscles).

Clinically, patients often have bilateral symmetrical proximal muscle weakness. Although the systemic disorder most frequently affects the skin and muscles but may also affect the joints, the esophagus, the lungs, and, less commonly, the heart. Dystrophic calcinosis may complicate dermatomyositis and is most often

observed in children and adolescents. If not treated, the disease can cause many serious complications such as macrophage activation syndrome, severe muscle weakness, damage to multiple organs, and even death.

Nowadays, the exact cause of DM is unclear. The pathogenesis is complex with the involvement of many factors and is not fully understood. Several studies suggest that infectious agents, medications, and environmental factors may be responsible for the onset of polymyositis and dermatomyositis. Genes may also have an essential role in the pathogenesis of the disease.²

According to EURLAR/ACR in 2017, the classification criteria for DM diagnosis is:³

Heliotrope rash or Gottron's papules or Gottron's sign.

Objective symmetric weakness, usually progressive, of the proximal upper extremities or,

Corresponding author: Nguyen Thi Dieu Thuy

Hanoi Medical University

Email: nguyendieuthuyhmu@gmail.com

Received: 22/11/2021

Accepted: 28/12/2021

Objective symmetric weakness, usually progressive, of the proximal lower extremities or,

Neck flexors are relatively weaker than extensors or,

In the legs, proximal muscles are relatively weaker than distal muscles.

Guidelines for the treatment of DM are limited, especially in children. In recent years, several consensus have been published to guide the treatment of DM in the first two months of the disease.⁴ These recommendations include using corticosteroids and methotrexate with or without combination with intravenous immunoglobulin (IVIg).⁴ Other immunosuppressive drugs such as mycophenolate mofetil, azathioprine, cyclosporin, or biologics (rituximab) are used when the disease has not responded to initial therapy. Prednisolone in combination with cyclosporine A shows similar therapeutic efficacy but resulted in more adverse effects than combined with methotrexate.⁵ Hydroxychloroquine is used in the treatment of skin lesions.⁶

IVIg is an immunomodulatory therapy for autoimmune diseases, including inflammatory myopathies.⁷ Few studies investigated the feasibility and safety of subcutaneous immunoglobulin (SCIg) in these rare conditions. Cherin reported a retrospective review of 19 cases with long-term subcutaneous immunoglobulin use in inflammatory myopathies, including polymyositis, dermatomyositis, and inclusion body myositis. The results suggest that the use of high-dose SCIg is feasible, beneficial, and safe. SCIg could be an alternative to IVIg in patients with inflammatory myopathies with insufficient response or in home care setting.⁸

Using subcutaneous immunoglobulin (SCIg) is advantageous because it can be applied at home and maintains stable blood gammaglobulin levels than IVIg.⁹ Early diagnosis and treatment with appropriate

initial therapy help patients recover faster, reduce side effects of medications and flare-ups. IVIg is usually indicated for severe conditions and corticosteroid resistance or corticosteroid dependence.⁴ We report a case of a child with dermatomyositis who was initially treated with SCIg with good response.

II. A CASE REPORT

A boy had the onset of the disease at the age of 2 with redness of the face, neck, nape, Gottron's papules on the top part of the hand, specifically the knuckles and the joints of his fingers. One month before admission, the child gradually progressed symmetric proximal muscle weakness accompanied by muscle pain, limited mobility, difficulty climbing stairs and getting up from a seated position, difficulty swallowing, eating, or choking. A child had no fever, no mouth ulcer, no joint pain. He had a healthy history and his parents were normal. The child was first admitted to the Department of Allergy Immunology and Rheumatology of The National Children's Hospital in October 2018.

Blood tests reported an increase in white blood cell count (WBC): 16 G/l, neutrophils: 78%, platelets: 586 G/l, high erythrocyte sedimentation rate – ESR (1st hour: 40 mm, 2nd hour: 60 mm). Blood biochemical tests showed very high creatine phosphokinase -CK: 1840 U/l (reference range: 55 - 170 U/L), an increased AST: 135 U/l (reference range: 10-40 U/L), ALT: 120 U/l (reference range: 7-56 U/L), LDH: 504 U/l, and high CRP: 32 mg/l (reference range: < 6 mg/l). Autoimmune antibodies such as ANA, dsDNA, anti-Jo-1 antibody, anti-phospholipid antibody, anti-Sm antibody, RNP-70 were negative. MRI of the bilateral thigh muscles showed a high T1 and diffuse myositis (Figure 1). The child was suspected of dermatomyositis.

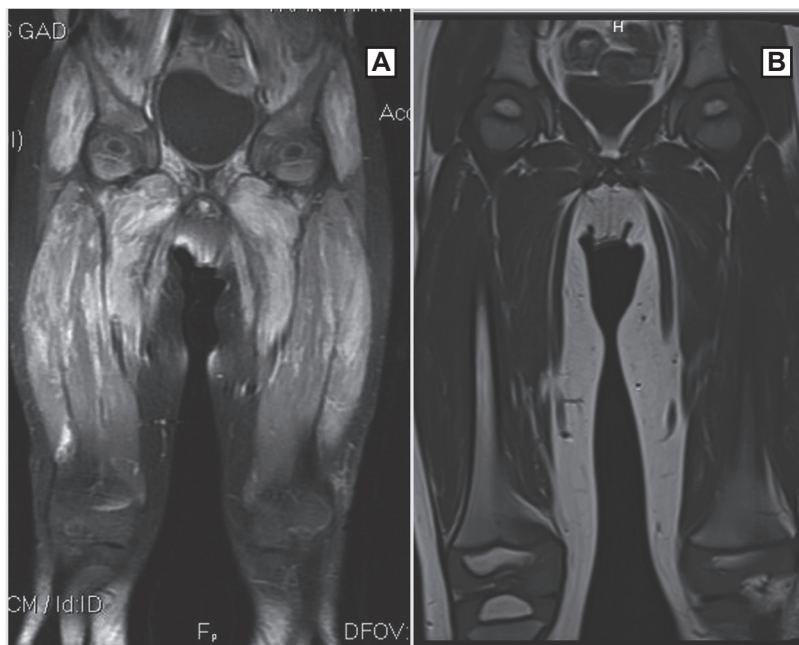


Figure 1. Diffuse inflammation of bilateral thigh muscle, high signal on T1 MRI before treatment (A), and image of thigh muscle returns to normal after one year of treatment (B)

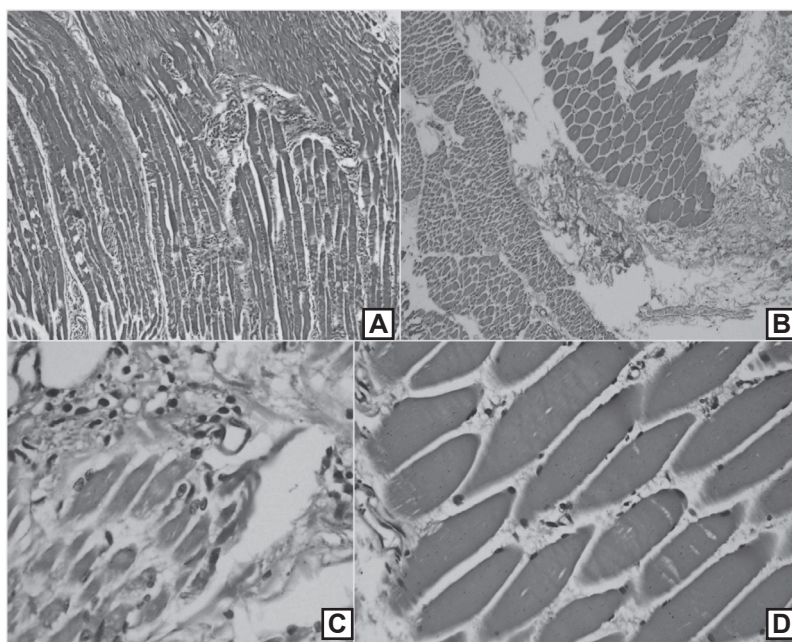


Figure 2. Histopathological picture of thigh muscle before and after one year of treatment. Before treatment, histopathology of muscle shows myositis included muscle fiber degeneration/regeneration and infiltration of neutrophils and lymphocytes (A. HE x 40, C. HE x 100). After treatment, the muscle fibers became seamless; there was no more inflammatory cell infiltration (B. HE x 40, D. HE x 400)

High muscle biopsy was performed. Histopathology, described as myositis, includes muscle fiber necrosis, degeneration, regeneration, and infiltration of neutrophils between the muscle fibers (Figure 2). Dermatomyositis was confirmed. The activities of myopathies are assessed using Myositis Disease Activity Assessment Tool (MDAAT- 2005) after long-term follow-up. This scale evaluates the activities in the last four weeks, including constitutional, cutaneous, skeletal, gastrointestinal, pulmonary, cardiovascular, extra-muscular, muscular, and other disease activities.¹⁰

The child was treated with bolus methylprednisolone 1000 mg/1.73 m² / day for three days, then reduced dose and switched to prednisolone 1 mg/kg/day in combination with methotrexate 15 mg/m²/week and hydroxychloroquine 5 mg/kg/day orally. After one week of treatment, there was improved muscle weakness, walking, and decreased Gottron's papules; laboratory tests demonstrated normal CK:173 U/l, AST: 50 U/l, ALT: 44 U/l, LDH: 320 U/l.

However, after 1 month of initial treatment, the child's muscle weakness relapsed with

increased Gottron's papule, CK increased to 600 U/l, AST to 60 U/l, ALT to 46 U/l. The child was add-on treated with subcutaneous immunoglobulin at a dose of 2g/kg/month for the first 6 months, then 0.3g/kg/month for the next 6 months. The evaluation of DM was good with improved muscle weakness, good climbing stairs, good running and jumping, no flare-ups.

We further reduced the prednisolone dose to 0.5 mg/kg/day after three months, to 0.3 mg/kg/day after the next three months, and 5 mg every other day for six months. After nine months of ceasing SCIg, prednisolone was discontinued. The duration of corticosteroid use was 18 months. Maintenance treatment continued with methotrexate at 15 mg/m²/week and hydroxychloroquine at 5 mg/kg/day. We had follow-up after one month and each 3 months after SCIg therapy; the progress of DM was quite good. no flare-ups, laboratory test results with CK, AST, ALT, CRP, ESR, LDH returning to normal ranges after one month (Table 1), muscle MRI returned to normal (Figure 1), and biopsy muscle (Figure 2) improved markedly after one year of treatment.

Table 1. Laboratory test results after SCIg therapy according to treatment time

Figures	1 month	3 months	6 months	9 months	12 months
WBC (G/L)	8.86	5.92	5.86	5.19	7.52
Platelets (G/L)	302	281	294	320	229
CRP (mg/L)	< 6	< 6	< 6	< 6	< 6
CK (U/L)	189	79	73	91	80
AST(U/L)	46	36	33	33	30
ALT(U/L)	18	15	11	12	12
LDH (U/L)	349	277	481	245	290
ESR 1h (mm)	20	8	15	5	5
ESR 2h (mm)	35	20	30	10	10

III. DISCUSSION

Immunoglobulin (Ig) is indicated for the treatment of autoimmune diseases such as dermatomyositis, which can be administered intravenously (IVIg) or subcutaneously (SCIg). This long-term IVIg therapy is associated with a risk of systemic adverse effects, high cost due to the need for intravenous access, surveillance, and hospitalization. For the majority of patients, IVIg and SCIg are equally efficacious. However, there are differences between therapies, particularly in the mode of administration (single large infusion every four weeks for IVIg, smaller doses once or twice a week for SCIg). Danieli et al. were the first to describe the feasibility and safety of SCIg in DM in 2011.¹¹ Previous studies have demonstrated that SCIg is safe, effective, having few complications and adverse effects. SCIg can be used at home, reducing hospital stays, children's absences from schools, and caregivers' absence from works, thus being more cost-effective than IVIg. Interestingly, SCIg is administered weekly, so the pharmacokinetics and bioavailability are different from IVIg given monthly; blood IgG levels have remained stable, and the treatment effect is more stable than IVIg.⁹

Immunoglobulin may affect myositis through a variety of mechanisms. The inhibitory effect of complement activation plays a vital role in treating dermatomyositis, limiting the muscle and skin damage caused by complement. Inhibition of cytokine production and expression of adhesion molecules may also contribute to the efficacy of Ig therapy. In dermatomyositis and polymyositis, Ig can regulate T-lymphocyte activation through directly or indirectly interactions with dendritic cells and macrophages by interfering with the Fc fraction receptor of IgG. The process of cell injury and death often observed in dermatomyositis, mediated by T CD8+ cells, may also be involved

in the Fas pathway. Ig regulates programmed cell death. Furthermore, Ig may ameliorate cytokine-dependent glucocorticoid resistance by improving glucocorticoid-binding receptors through an unknown mechanism, including inhibiting proinflammatory cytokine production.¹²

A study of patients with dermatomyositis and polymyositis treated with IVIg at 1 g/kg/day for two days every four weeks showed improved muscle strength and decreased CK levels. In 1993, Dalakas et al. reported a randomized, double-blind, placebo-controlled trial in 15 patients with refractory dermatomyositis. Patients were randomly administered to IVIg 2 g/kg or placebo monthly for three months. After three months, vice versa, the placebo group would randomly select some patients to receive IVIg therapy; the IVIg group would randomly select several patients to receive placebo. Eight patients in the IVIg group, but none in the placebo group, showed a significant improvement in muscle strength. After the reversal phase, 12 patients received IVIg, and patients showed a significant improvement in muscle strength. In the placebo-treated group, only three patients improved muscle strength.¹³

Muscle biopsies in patients with Ig therapy showed increased muscle fiber diameter, a decrease in capillary diameter and complement, especially C3b, and the microvascular deposition of complement *membrane attack complex*. Serum from IG-treated patients also inhibits C3 uptake *ex vivo*, suggesting that IG may play a role by inhibiting complement activation.¹⁴ Similarly, the muscle biopsy result of our patient improved after one year of treatment.

In immunocompromised patients, SCIg dose can be adjusted based on the patient's serum IgG level. However, there is no recommended

therapeutic dose of SCIg in patients with dermatomyositis. A study published in 2011 reported that SCIg can effectively treat dermatomyositis and polymyositis in adults at a dose of 0.8 mg/kg/month.¹¹ More recently, Gelardiet al. reported three adults with polymyositis and dermatomyositis treated with long term low maintenance doses of SCIg at 0.2-0.8 g/kg/month.¹⁵ Our patient was treated with an equal dose of IVIg for DM, which showed excellent results. After six months of SCIg induction therapy with a dose of 2 g/kg/month, the patient was switched to a maintenance dose of 0.3 g/kg/month for the next six months. At follow-up, the dose of corticosteroids was quickly reduced and discontinued after 18 months, limiting adverse effects of corticosteroids. Muscle weakness, skin redness significantly improved, and no flare-up for nine months after SCIg and corticosteroid cessation.

IV. CONCLUSION

Immunoglobulin is effective and safe in treating dermatomyositis, but due to the high cost, it is often indicated for patients who suffer from severe or do not respond to standard treatment. Early immunoglobulins treatment for patients with dermatomyositis resulted in early clinical improvement and less dependence on corticosteroids. Subcutaneous immunoglobulin helps to maintain stable blood immunoglobulin levels. Long-term studies with more significant numbers of patients are needed to evaluate the long-term efficacy of SCIg.

REFERENCES

1. Aussy A, Boyer O, Cordel N. Dermatomyositis and Immune-Mediated Necrotizing Myopathies: A Window on Autoimmunity and Cancer. *Front Immunol.* 2017; 8:992. Published 2017 Aug 21. doi:10.3389/fimmu.2017.00992.

2. DeWane ME, Waldman R, Lu J. Dermatomyositis: Clinical features and pathogenesis. *J Am Acad Dermatol.* 2020; 82(2):267-281. doi:10.1016/j.jaad.2019.06.1309

3. Lundberg IE, Tjärnlund A, Bottai M, et al. 2017 European League Against Rheumatism/American College of Rheumatology classification criteria for adult and juvenile idiopathic inflammatory myopathies and their major subgroups [published correction appears in *Ann Rheum Dis.* 2018 Sep; 77(9):e64]. *Ann Rheum Dis.* 2017; 76(12): 1955-1964. doi:10.1136/annrheumdis-2017-211468.

4. Huber AM, Giannini EH, Bowyer SL, et al. Protocols for the initial treatment of moderately severe juvenile dermatomyositis: results of a Children's Arthritis and Rheumatology Research Alliance Consensus Conference. *Arthritis Care Res (Hoboken).* 2010; 62(2): 219-225. doi:10.1002/acr.20071

5. Ruperto N, Pistorio A, Oliveira S, et al. Prednisone versus prednisone plus ciclosporin versus prednisone plus methotrexate in new-onset juvenile dermatomyositis: a randomised trial. *Lancet.* 2016; 387(10019): 671-678. doi:10.1016/S0140-6736(15)01021-1

6. Stringer E, Bohnsack J, Bowyer SL, et al. Treatment approaches to juvenile dermatomyositis (JDM) across North America: The Childhood Arthritis and Rheumatology Research Alliance (CARRA) JDM Treatment Survey. *J Rheumatol.* 2010; 37(9): 1953-1961. doi:10.3899/jrheum.090953

7. Cherin P, Herson S, Wechsler B, et al. efficacy of intravenous gammaglobulin therapy in chronic refractory polymyositis and dermatomyositis: an open study with 20 adult patients. *Am J Med.* 1991; 91(2): 162-168. doi:10.1016/0002-9343(91)90009-m.

8. Cherin P, Belizna C, Cartry O, et al. Long-term subcutaneous immunoglobulin use in

inflammatory myopathies: A retrospective review of 19 cases. *Autoimmun Rev.* 2016; 15(3): 281-286. doi:10.1016/j.autrev.2015.12.003.

9. Abolhassani H, Sadaghiani MS, Aghamohammadi A, Ochs HD, Rezaei N. Home-based subcutaneous immunoglobulin versus hospital-based intravenous immunoglobulin in treatment of primary antibody deficiencies: systematic review and meta analysis. *J Clin Immunol.* 2012; 32(6): 1180-1192. doi: 10.1007/s10875-012-9720-1

10. Lazarevic D, Pistorio A, Palmisani E, et al. The PRINTO criteria for clinically inactive disease in juvenile dermatomyositis. *Ann Rheum Dis.* 2013; 72(5): 686-693. doi:10.1136/annrheumdis-2012-201483.

11. Danieli MG, Pettinari L, Moretti R, Logullo F, Gabrielli A. Subcutaneous immunoglobulin in polymyositis and dermatomyositis: a novel application. *Autoimmun Rev.* 2011; 10(3): 144-

149. doi:10.1016/j.autrev.2010.09.004.

12. Gelfand EW. Intravenous immune globulin in autoimmune and inflammatory diseases. *N Engl J Med.* 2012; 367(21): 2015-2025. doi:10.1056/NEJMra1009433

13. Dalakas MC, Illa I, Dambrosia JM, et al. A controlled trial of high-dose intravenous immune globulin infusions as treatment for dermatomyositis. *N Engl J Med.* 1993; 329(27): 1993-2000. doi:10.1056/NEJM199312303292704.

14. Choy EH, Isenberg DA. Treatment of dermatomyositis and polymyositis. *Rheumatology (Oxford).* 2002; 41(1): 7-13. doi:10.1093/rheumatology/41.1.7.

15. Gelardi C, Paolini L, Danieli MG. Subcutaneous immunoglobulin G in idiopathic inflammatory myopathies: therapeutic implications. *Isr Med Assoc J.* 2014; 16(10): 646-647.