

A CASE REPORT OF THE FIRST HEREDITARY TRANSTHYRETIN CARDIAC AMYLOIDOSIS DIAGNOSED IN VIETNAM

Duong Thu Anh^{1,✉}, Nguyen Thi Ngoc Lan², Le Manh Ha³

¹Bach Mai Hospital

²Hanoi Medical University

³108 Military General Hospital

Amyloid cardiomyopathy is a cardiovascular disease characterized by infiltration of amyloid into the heart muscle and other organs in the body, triggering impaired function of the heart and other organs. There are three main subtypes of amyloidosis including primary or AL amyloidosis, secondary or AA amyloidosis and hereditary or familial amyloidosis. Hereditary amyloidosis is less common, caused by an autosomal-dominant mutation most frequently in the transthyretin gene and has a more favorable prognosis.^{1,3} In this paper, we will be looking into a rare case of hereditary transthyretin amyloid disease with a genetic mutation (mutant TransThyRetin Amyloidosis - ATTRm), the first to be reported in Vietnam. That is a 47-year-old Vietnamese man with various clinical manifestations, including gastrointestinal disturbances (diarrhea, watery stool), periorbital purpura, macroglossia, autonomic neuropathy (dizziness, orthostatic hypotension, limb numbness, faint), and cardiovascular symptoms (dyspnea, leg edema, severe heart arrhythmias). The patient has a notable family history of many members appeared to have shown signs of the same disease and passed on without a diagnosis. A multimodality team in hematology, nuclear medicine, genetics, dermatology, and cardiology was assigned to the patient. We concluded that the patient was suffering from a form of ATTRm with a different genetic mutation from the common gene mutation in the world. Our patient is currently enrolled in a research program with a pharmaceutical manufacturer providing specific treatment and free medication. He is responding well to treatment and has shown signs of improvement.

Keywords: ATTR, amyloidosis, polyneuropathy, case report, c.209G>T (p.Ser70Ile).

I. INTRODUCTION

Amyloid cardiomyopathy is a cardiovascular disease characterized by the infiltration of amyloid into the heart muscle and other organs in the body, triggering impaired function of the heart and other organs. The disease has two main types: light chain Amyloidosis (AL) and transthyretin (TransThyRetin Amyloidosis - ATTR). This is a rare disease with an incidence rate of about 5-8 cases per million people in the US and UK.²

We have diagnosed a patient presenting with very complex and varied symptoms with the TTR Amyloid disease, which we believe should be the first to be reported in Vietnam.

In this paper, we would like to share some of the experiences and findings in the journey of diagnosing the patient with this rare form of TTR Amyloid. We believe the information in this paper would be beneficial for both clinical and educational purposes.

II. CASE STUDY

The patient is a 47-year-old Vietnamese businessman who suffered from severe dizziness and fainting episodes for a week before being transferred to our hospital. The ECG at admission

Corresponding author: Duong Thu Anh

Bach Mai Hospital

Email: anhd.23729@bachmai.edu.vn

Received: 28/02/2021

Accepted: 08/02/2022

showed a-third-grade atrioventricular block with a heart rate of only 12-15 beats per minute (bpm) and blood pressure of 60/40 mmHg. The patient was put on inotrope and had a temporary pacemaker inserted to improve cardiac output and to restore hemodynamic stability. After three days, a permanent dual-chamber magnetic resonator imaging (MRI) compatible pacemaker was implanted.

Family Medical History

The patient has a remarkable family medical history. His paternal grandmother, uncles, cousin, father, and 3 of his siblings all had similar symptoms. Unfortunately, all of them passed away without ever finding the cause of their symptoms. The patient also has a 42-year-old younger brother who does not have any sign of the disease.

Patient Medical History

The patient began to have defecation disorder about eight years ago, resulting in watery stools, especially after eating. The defecating problem worsened over time, causing severe languishment and a weight loss of 20kg . At admission, his height was 1.58 m, weight 37 kg, and BMI of 14.8 kg /m2.

After L4-L5 spinal disc surgery in 2018, the patient experienced constant aching and gradual loss of strength in his lower limbs. Aching is especially pronounced during exertion.

About two years ago, the patient started experiencing tiredness, breathlessness. He also felt dizziness, faintness whenever he sat up. Spontaneous bruising also started appearing on the left eyelid area.

Patients sought treatment from different hospitals both in Vietnam and Singapore. He underwent many diagnostic examinations and tests, such as gastrointestinal endoscopy and brain MRI. However, doctors were unable to

pinpoint an exact diagnosis or specific treatment for his condition.

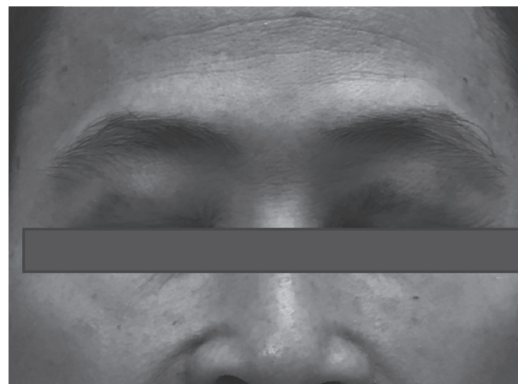
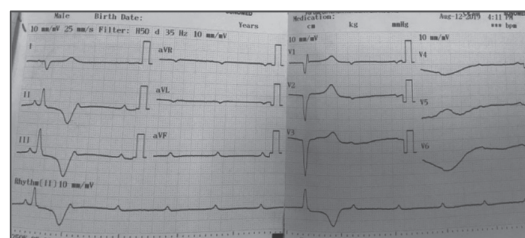


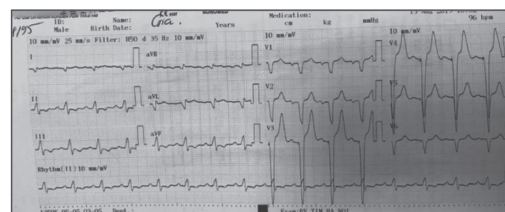
Figure 1. Periorbital purpura in the eyelids

Diagnostic Assessment

On admission, the ECG showed third-degree atrioventricular block with dangerously low ventricular frequency, only about 12-15 beats per minute (bpm). After implantation of a temporary pacemaker, the heart rate increased to # 96 bpm, with sinus rhythm.



2a



2b

Figure 2. ECG at emergency department (2a) shows third-degree heart block with a remarkably prolonged heart rate of 12 bmp. Post temporary pacemaker implant ECG (2b) shows a sinus rhythm, 96 bpm

Echocardiography revealed very thick and bright heart muscle walls, with preserved left ventricular systolic function (EF 58%). However, there was severe diastolic dysfunction. Speckle

tracking echocardiography showed a preserved global longitudinal strain (GLS) at the apex and decreased in the mid and basal portion of the left ventricle (cherry on the top pattern).

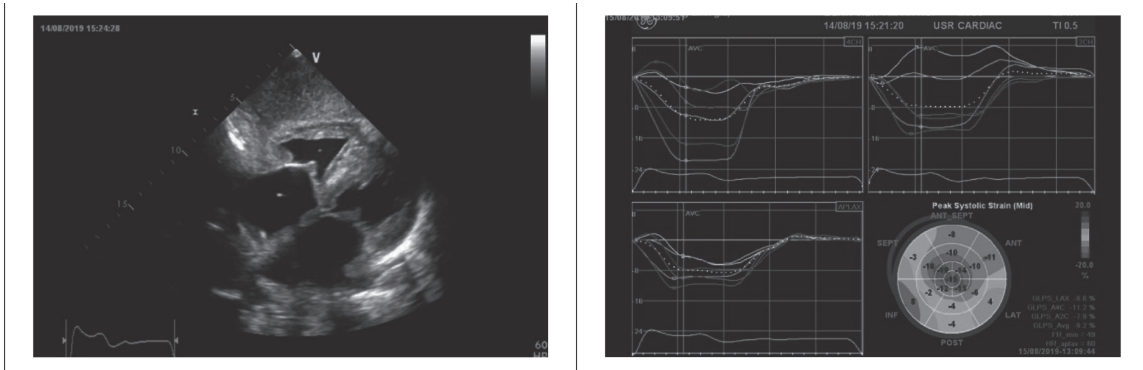


Figure 3. Echocardiography

Cardiac magnetic resonance shows diffuse late gadolinium enhancement in both ventricles and atriums with a significant wall

thickness of # 18 mm, minimal pericardial effusion. It preserved left ventricle function with EF of # 60%.

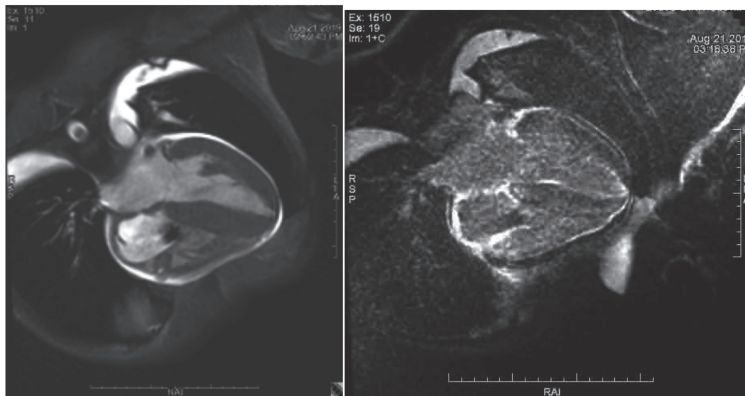


Figure 4. diffuse late gadolinium enhancement on cardiac magnetic resonance

Coronary angiography: no lesion.

Blood test shows renal dysfunction with eGFR 34 ml/min, myocardial trauma with high Troponin T hs of 252 pg/mL, and heart failure with NTproBNP of 13259 pg/mL. Serum immunofixation reveals a slight increase of free

kappa (60.5 mg/L) and free lambda (71.5 mg/L), however the κ/λ ratio is normal (0.84). Other tests that helped us rule out the diagnosis of primary amyloidosis were aspiration and biopsy of the abdominal fat, as well as a tongue biopsy which were all negative for Congo red spot.

^{99m}Technitium-Pyrophosphate imaging findings are strongly suggestive of TTR amyloidosis with a semi-quantitative visual score of 3 and heart/contralateral ratio (H/CL ratio) = 2.1.

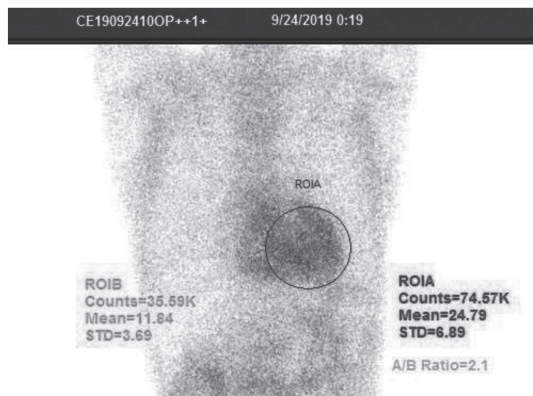


Figure 5. Quantitation of Cardiac ^{99m}Tc-PYP uptake using Heart to Contralateral Lung (H/CL) ratio = 2.1

To confirm the hereditary ATTR subtype, the patient's blood was sent to Green Cross Laboratories (South Korea), using PCR & Sequencing (Total 4 exons) method. The result shows heterozygous for c.209G>T (p.Ser70Ile), which are known to be hereditary ATTR.

Treatment

A dual-chamber permanent pacemaker (MRI compatible) was implanted. The patient was also given low-dose vasopressors to stabilize blood pressure, digestive enzyme supplements to relieve digestive disorders and general vitamins. The fainting condition improved after the pacemaker implantation. However, blood pressure remained low at around 80/60 mmHg, and fainting episodes still occurred when the patient changed positions. The patient's digestive status also did not improve. There was still a watery bowel movement 15 minutes after eating. Based on the above test results and imaging diagnosis, we concluded that the patient had

hereditary ATTR-type amyloid. However, treatment for this disease in Vietnam has not been previously reported. Hence, we sent the patient's profile to our fellow counterparts in the US and were referred to a hospital in Chicago where targeted treatment for ATTR-type amyloid disease is available. Our American colleagues confirmed the diagnosis of ATTRm based on the test results and diagnostic imaging examinations performed in Vietnam. Our patient was recruited for a research program in the US for medication that targeted the disease - a short double-stranded interfering RNA transported to the liver. However, due to the COVID-19 pandemic, the patient's treatment in the US was cut short, however, the treatment was continued at a hospital in Hanoi,

Outcomes

After six rounds of infusion of the medication in Vietnam, our patient has gained 3 kg. His leg pain was relieved, his orthostatic hypotension reduced, and his digestion gradually improved. His most recent kidney function has also shown significant improvement with eGFR of 63.3 ml/m (CKD-EPI method).

III. DISCUSSION

Transthyretin amyloidosis (ATTR) is a disease caused by abnormal fibrils derived from TTR (transthyretin), a protein produced mainly by the liver, which aggregate and deposit in tissues and organs.^{1, 2} Cardiomyopathy is a common manifestation of ATTR amyloidosis (ATTR associated with cardiomyopathy [ATTR-CM]) and is associated with a particularly poor life expectancy of 2 to 6 years after diagnosis. Patients with ATTR-CM experience debilitating physical symptoms common to heart failure (HF), such as exercise intolerance and fatigue, resulting in decreased functional capacity, diminished quality of life, and eventual death. ATTR-CM can be acquired through the

aggregation of wild-type TTR (ATTRwt) or inherited from a variety of genetic variants of TTR (mutant transthyretin amyloidosis [ATTRm]; also known as hereditary ATTR).³

Based on the consensus recommendation for suspicion and diagnosis of cardiac amyloidosis published in the Circulation Heart Failure in September 2019, when electrocardiogram, echocardiography, cardiac MRI, and biological markers suggest amyloidosis, it is necessary to screen for the presence of monoclonal proteins by three assays: the ratio of serum-free light-chain kappa/lambda (abnormal if this ratio is less than 0.26 or greater than 1.65), serum protein immunofixation (abnormal if monoclonal proteins are detected) and urine protein immunofixation (abnormal if monoclonal proteins are detected). For patients with ATTR-type Amyloid, these tests are normal.⁴

The patient had sought medical treatment in many places for the main manifestations of digestive and neurological symptoms. Unfortunately, no specific diagnosis was found.

However, we can narrow down the diagnosis based on the following steps. Firstly, the patient's cardiovascular symptoms and the thick bright wall of his heart in the echocardiography point toward Amyloid cardiomyopathy. Secondly, the results of Myocardial perfusion with 99m Pyrophosphate indicates ATTR Amyloidosis. And finally, the abnormal genetic test confirmed this form ATTR Amyloidosis is hereditary

Hereditary transthyretin (ATTRv) amyloidosis, or transthyretin-type familial amyloid polyneuropathy, is an autosomal dominant, adult onset, rare systemic disorder caused by mutations in the transthyretin (*TTR*) gene.^{5,6}

The result of the genetic mutation of our patient has been less recognized in the literature. The most common variant globally is

the Val122Ile (or pV142I), which occurs in 3-4% of black Americans and has undetermined gene penetrance.⁷ The primary clinical manifestation of this TTR Val122Ile variant is cardiomyopathy. It is estimated that about 10% of black Americans with heart failure over the age of 60 carry this variant TTR Val122Ile. With manifestations of neuropathy, the Val30Met variant is the most common.⁸ Our patient's genetic mutation result was heterozygous c.209G> T (p.Ser70Ile). The ATTR Ser50Ile has been reported in two Japanese patients by Nishi and Saeki. The PCR products of the transthyretin gene were denatured in the presence of formamide and electrophoresed in a non-denaturing polyacrylamide gel to detect an electrophoretic change due to a sequence variation. An unusual DNA fragment was visualized by silver staining in the patient's PCR products of the exon 3. Subsequent sequencing analysis revealed a T to A transversion and replaced Ser by Ile at codon 50 of the TTR gene. This mutant TTR gene in a patient with familial cardiac amyloidosis showed no apparent polyneuropathy. Saeki found the exon three variants at the 50th codon, AGT coding for Ser change to ATT coding for Ile. The mechanism by which variant TTR molecules are deposited is not fully understood. We suggest that a mutation at phylogenetically conserved sites of the TTR molecule might be necessary for the amyloid formation.^{9,10}

The first autopsy case report of Sakashita (2000) described clinical-pathological findings for two cases of familial amyloid polyneuropathy with the single amino acid mutation ATTR Ser50Ile clinicopathological demonstrated a systemic amyloid deposition in various organs and tissues of an autopsy case. Initial signs and symptoms in familial amyloid polyneuropathy (ATTR Ser50Ile) differ from typical familial amyloid polyneuropathy (ATTR Val30Met).

However, cardiac symptoms, especially congestive heart failure, became prominent in the early clinical course.¹¹ Consistent with the present cases, previous reports noted (1) that the most critical problems in this type of mutation were severe cardiac failure and fatal arrhythmia and (2) that pacemaker implantation could improve prognosis¹². This present examination revealed significant amyloid deposition in the cardiovascular system, similar to that described in previous autopsy reports of Ser50Arg and Tyr114Cys types of TTR-related familial amyloid polyneuropathy.^{13,14} The total amount of amyloid in the heart of the present autopsy case was huge, compared with that in 20 cases of familial amyloid polyneuropathy (ATTR Val30Met) previously reported in our laboratory.^{13,15}

The ATTR Ser50Ile was reported in several researches from Japan.^{12,16} DNA sequencing analysis of Sadamatsu et al (1997) showed that patient 2 had a 50TTR Ile mutation. The clinical features of this patient were sensory-motor polyneuropathy with autonomic dysfunction and amyloid cardiomyopathy. This 58-year-old Japanese woman had experienced a syncope attack and palpitation on exercise and paresthesia in the lower extremities for four years. Massive amyloid deposits were detected in her rectum. The ages at onset of these four patients were all in the fourth or fifth decade of life. Familial amyloid polyneuropathy associated with the TTR Ile 50 mutation thus is likely to have its onset during middle age and mainly affect the peripheral nerves and heart.¹²

IV. CONCLUSION

This is a case of hereditary ATTRm with a form of genetic mutation so rare that it is reported for the first time in Vietnam. Our experience with the case suggests that a multidisciplinary

approach may be needed to successfully diagnose the disease. We propose a diagnosis for ATTRm should be performed for patients with collective symptoms of digestive disorders, fainting episodes, and heart arrhythmias. One of the obstacles in Vietnam is that there is no specific treatment available and due to the high cost of the medicine the treatment is out of reach for most people in Vietnam. We propose that orphan diseases medication should be covered under the health insurance plan so that treatment can be more affordable.

REFERENCES

1. Hiroyuki Y, Tomoki Y. Transthyretin cardiac amyloidosis: an update on diagnosis and treatment. *ESC Heart Fail*, 2019;6(6):1128-1139.
2. Quock PT, Yan T, Chang E et al. Epidemiology of AL amyloidosis: a real-world study using US claim data. *Blood Adv*, 2018; 2(10):1046-1053.
3. Hassan W, Al-Sergani H, Mourad W, Tabbaa R. Amyloid heart disease – new frontiers and insights in pathophysiology, diagnosis and management. *Tex Heart Inst J*, 2015; 32(2): 178-184.
4. Maurer M S et al. Expert consensus recommendations for the suspicion and diagnosis of transthyretin cardiac amyloidosis. *Cir Heart Fail*, 2019; 12(9):e006075.
5. Y. Ando, T. Coelho, J. L. Berk et al. Guideline of transthyretin-related hereditary amyloidosis for clinicians. *Orphanet J f Rare Dis*, 2013; 8(1),31.
6. Y. Sekijima, M. Ueda, H. Koike et al. Diagnosis and management of transthyretin familial amyloid polyneuropathy in Japan: red-flag symptom clusters and treatment algorithm. *Orphanet J Rare Dis*, 2018; 13(1),6.
7. Ruberg F L, Grogan M, Hanna M, Kelly W J, Maurer M. Transthyretin Amyloid

Cardiomyopathy: JACC State-of-the-art review. *J Am Coll Cardiol*, 2019; 73(22): 2872-2891.

8. Bruno M, Castano A, Burton A, Grodin J. Transthyretin amyloid cardiomyopathy in women: frequency, characteristics and diagnosis challenges. *Heart Fail Rev*, 2021; 26: 35-45.

9. H. Nishi, A. Kimura, H. Harada et al. Novel variant transthyretin gene (Ser50 to Ile) in familial cardiac amyloidosis. *Biochem Biophys Res Commun*, 2012; 187(1): 460-466.

10. N. Sakashita, Y. Ando, K. Obayashi et al. Familial amyloidotic polyneuropathy (ATTR Ser50Ile): the first autopsy case report. *Virchows Archiv*, 2000; 436 (4): 345-350.

11. N. Sakashita, Y. Ando, K. Obayashi et al. Familial amyloidotic polyneuropathy (ATTR Ser50Ile): the first autopsy case report. *Virchows Archiv*, 2000; 436 (4):345-350.

12. K. Sadamatsu, Y. Hayashi và M. Nakamura. Three siblings of familial amyloid cardiomyopathy with isoleucine-50 transthyretin

mutation. *Int J Cardiol*, 1997; 61(2): 151-155.

13. K. Takahashi, S. Yi, Y. Kimura et al. Familial amyloidotic polyneuropathy type 1 in Kumamoto, Japan: a clinicopathologic, histochemical, immunohistochemical, and ultrastructural study. *Hum Pathol*, 1991; 22(6): 519-527.

14. S. Ueno, H. Fujimura, S. Yorifuji et al. Familial amyloid polyneuropathy associated with the transthyretin Cys114 gene in a Japanese kindred. *Brain*, 1992; 115(Pt 5): 1275-1289.

15. N. Takahashi, S. Ueno, T. Uemichi et al. Amyloid polyneuropathy with transthyretin Arg50 in a Japanese case from Osaka. *J Neurol Sci*, 1992; 112(1-2): 58-64.

16. Y. Date, M. Nakazato, K. Kangawa et al. Detection of three transthyretin gene mutations in familial amyloidotic polyneuropathy by analysis of DNA extracted from formalin-fixed and paraffin-embedded tissues. *J Neurol Sci*, 1997; 150(2): 143-148.