

FIRST CD3/CD45RA DEPLETED HAPLOIDENTICAL TRANSPLANT FOR SEVERE COMBINED IMMUNODEFICIENCY DISEASE WITH ROTAVIRUS GASTROENTERITIS IN VIETNAM

Nguyen Thanh Binh^{1,2}, Dang Anh Duong¹, Bui Ngoc Lan¹
Nguyen Thi Van Anh¹, Tran Quynh Huong³, Le Thi Minh Huong¹
Cao Viet Tung¹, Tran Minh Dien¹ and Nguyen Ngoc Quynh Le^{1,✉}

¹Vietnam National Children's Hospital

²Hanoi Medical University

³Children's Hospital, HCM

Severe combined immunodeficiency includes inherited diseases with impairment of T cells development, often associated with profound defects of B and/or NK cells differentiation. Rotavirus infection is responsible for severe acute gastroenteritis and over 400,000 deaths a year in children aged < 5 years, especially in low and middle-income countries. We report a nine-month-old girl presented with failure to thrive left axillary lymphadenitis post-BCG-vaccination, persistent, nonvaccine-associated rotavirus gastroenteritis. An immune evaluation revealed absent T lymphocytes, B lymphocytes, normal NK cells with genetic testing confirmed RAG2 severe combined immunodeficiency. Rotavirus gastroenteritis persisted despite the administration of oral immunoglobulin pre-transplantation. The patient was treated by a haploidentical transplant -from mother as a donor using CD3/CD45RA+ depletion kit, CliniMACs system (Miltenyi). The first transplant was performed without conditioning. One month post-transplant, rotavirus was cleared. The second transplant was performed three months later, with myeloablative conditioning (Bu-Flu-rATG). Neutrophils engrafted on day +10 post-transplant, platelet engrafted on day +45. Whole blood chimerism on day +28 post 2nd transplant was 100%. Serum IgG level has been normalized without IVIG infusion three months post 2nd transplant.

Keywords: SCID, Rotavirus gastroenteritis, haplo transplant, CD3/CD45RA depletion.

I. INTRODUCTION

Severe combined immunodeficiency (SCID) is a heterogeneous group of monogenetic diseases characterized by the disturbed development of functional T cells and B cells caused by numerous genetic mutations resulting in differing clinical presentations.¹ In the US, the estimated annual incidence of SCID is one case per 75,000 - 100,000 live births, or a total of approximately 40- 100 new cases among infants.² SCID

patients are affected by severe bacterial, viral, or fungal infections in early life and often present with interstitial lung disease, chronic diarrhea, and failure to thrive. Ear infections, recurrent *Pneumocystis jirovecii* pneumonia, and profuse oral candidiasis commonly occur.⁷ Treatment of viral infections before hematopoietic stem cell transplantation (HSCT) with intravenous immunoglobulin (IVIG) and antivirals has been attempted, but the persistence of viral infection has been reported.^{3,4,5}

Rotavirus infection is responsible for severe acute gastroenteritis and cause over 400,000 deaths a year in children aged < 5 years, especially in low-income countries.⁶ Chronic

Corresponding author: Nguyen Ngoc Quynh Le

Vietnam National Children's Hospital

Email: dr.quynhle@gmail.com

Received: 07/01/2022

Accepted: 16/02/2022

rotavirus infection can result from patients with underlying primary immunodeficiency, especially severe combined immunodeficiency.⁴ The most common treatment protocol for SCID patients included guarding against infection, avoiding “live” vaccinations, monthly intravenous immunoglobulin infusion and allogeneic stem cell transplantation as soon as possible. SCID babies, if untreated, usually die within one year of life due to severe, recurrent infections unless they have undergone successful hematopoietic stem cell transplantation. An HLA- matched sibling is the donor of choice for all SCID types. If a matched sibling or a well-matched unrelated donor cannot be identified timely, or if the patient has an active infection, a familial haploidentical transplant should be considered.⁸ The extensive *ex-vivo* depletion of donor T-cells (CliniMACS system) has proven efficient in preventing graft-versus-host disease (GvHD). Besides, *ex-vivo* T- cells depletion retain beneficial memory T- cells (CD45RO) in the haploidentical graft against viral infection.⁹

Herein, we report on the successful treatment of SCID with rotavirus gastroenteritis and BCG lymphadenitis by CD3/CD45RA T cell-depleted haploidentical.

II. CASE REPORT

The baby girl was born at full term, with a normal pregnancy, as the second child of non-consanguineous parents. Both parents and sibling are healthy. She had received the BCG vaccine at three weeks of age.

The baby developed chronic intermittent diarrhea at two months of age and was diagnosed with cow’s milk allergy, but there was no progress. She had palpable redness and painful left axillary lymph nodes at three months old. Biopsy from left axilar lymphadenitis was (+) with *Mycobacterium Bovis* (BCG) and

was treated with Rifampicin, Isoniazid, and Ethambutol for 2 months. The lymphadenitis and diarrhea worsened; consequently, she was hospitalized at a referential children’s hospital with respiratory distress and diarrhea. She was treated at that hospital for over three months with a diagnosis of persistent diarrhea, oral intolerance, bronchiolitis, oral thrush, and failure to thrive. The unusually severe course of the infection and the failure to thrive suggested a primary immunodeficiency disorder. She was transferred to the National children’s hospital for further analysis.

A peripheral white blood cell count was 16,800 cells/ μ l with 69% neutrophils, 2% lymphocytes (absolute lymphocyte count = 320 cells/ μ l [normal range 2,000 - 5,000]), 7% monocytes, and 13% eosinophils. Other laboratory tests were normal, including electrolytes, pancreatic amylase, bilirubin, organic acids, amino acids, and thyroid hormone.

Considering her faltering growth, severe persistent infections, persistent thrush and a low lymphocytes count, further immunological tests were conducted. Nearly undetected levels of IgG were found (0.3 g/L; normal range: 2.32-14.11 g/L), IgA (0.05 g/L; range: 0- 0.83 g/L) and IgM (0.09 g/L; range: 0- 1.45 g/L). Therefore, lymphocyte subset had been ordered for patient. The CD3⁺ T cells were severely low (1 cells/mm³, normal range 1000–2100 cells/mm³), no CD19⁺ B cells (0 cells/mm³, normal range 700–1100 cells/mm³), and normal CD3⁻CD56⁺ NK cells (560 cells/mm³, normal range 300– 600 cells/mm³).

Bronchoalveolar lavage revealed *Acinetobacter baumannii*, blood culture revealed *Candida parapsylosis*. Stool analysis by SD bioline rotavirus antigen (Abbott) was positive. A homozygous mutation was present in recombination activating gene 2 (RAG2), consistent with SCID diagnosis.

Multiple doses of IVIG (Kedrigamma®, Kedrion, Italy) were given before transplantation, including two episodes of 100 mg/kg/day for five days administered orally at eight months of age. The patient also was treated with broad-spectrum antibiotics antifungal drugs (Caspofungin) and maintained treatment with Rifampicin and Isoniazid for TB prophylaxis. Considering the low numbers of lymphocytes and the life-threatening infections, the decision was made to perform a HSCT. According to our institutional protocol for haploidentical HSCTs, the parents provided written informed consent for this procedure. No HLA-matched siblings were available, and the probability of finding a matched unrelated donor was low in Vietnam. Consequently, the choice was made to select an HLA- haploidentical parental donor.

Transplant protocol

Due to her lymphocyte subset and genetic defect, the patient needs myeloablative conditioning to achieve engraftment. Without training and engraftment at the stem cell level, T-cell will be derived only from T-cell precursors or immature T-cells from the donor graft, with no B-cell reconstitution. On the other hand, chemo conditioning causing mucositis will further damage the gut resulting in severe impairment, busulfan can exacerbate lung damage. Pre-existing lung and gut damage will further worsen graft-versus-host disease due to host HLA antigen upregulation in the inflamed tissue. The final decision was to perform two-stage T-cell depleted transplant procedure . T-cell repleted with post- Cyclophosphamide was not recommended because of the toxicity of cyclophosphamide. First unconditioned or low dose Bu/Flu conditioning will follow by CD3/CD45RA depletion. If the patient stabilized with improved organ function, we would continue with complete conditioning as a definitive transplant

procedure, infuse cryopreserved CD3/CD45RA depleted PBSC collected from the first harvest.

Donor selection

The patient and her parents were investigated high-resolution allelic typing for HLA- A*, -B*, -C*, DRB1*, DQB1*, BPB1* by PCR- SSO (Luminex), ABO- blood grouping, and CMV- serology. The mother was selected as the donor based on the outcome of the pre-transplant investigation. The HLA- typing confirmed patient and donor has 7/10 HLA matched (one allelic mismatched in HLA-A, HLA- B, HLC- C). The patient and the donor were matched for ABO- blood group and were both CMV IgG positive.

Graft engineering

The haploidentical maternal donor's peripheral blood stem cells (PBSCs) were mobilized by a granulocyte-colony-stimulating factor (G-CSF, 10 µg/kg/day) for four days. A single leukapheresis procedure (The COMTEC® Apheresis System, Fresenius, Germany) provided 59×10^6 CD34+ cells/kg recipient weight for subsequent CD3/CD45RA depletion with the CliniMACS System. A 9/10 of portion went to CD3+ depletion, 1/10 of the piece went to CD45RA+ deficit. The recovery of CD34+ cells and CD45RO+ was 99%.

According to the manufacturer's protocol, collected PBPCs were processed under cleanroom conditions with the CliniMACS system (Miltenyi Biotech). The cells were sequentially labeled with CD3/CD45RA Biotin reagent and CliniMACS anti-Biotin reagent and processed with the CliniMACS device using the D3.1 program with the Depletion Tubing Set (DTS). The graft cell contents were determined by flow cytometric analysis (FACS, Canto II, Becton Dickinson [BD]), using antibodies against CD45, CD34, CD14, CD19, CD56, CD3. The graft was split into two portions, one given fresh, the other

cryopreserved for the 2nd definitive transplant. Each depletion procedure provides a stem cell and T-cell product sufficient for two transplant procedures. The target cell dose of the CD3/CD45RA depleted graft was set to 10×10^6 CD34+ cells/kg (minimum 5×10^6 CD34+/kg), 1×10^6 CD3+CD45RO+ cells/kg. Three bags of CD3CD45RO+ were cryopreserved for donor lymphocyte infusions (DLI) with cell doses were: 0.5×10^6 /kg, 1.0×10^6 /kg, 2.0×10^6 /kg body weight of recipient.

First transplantation

At nine months of age, the patient underwent the first transplant from the mother without chemotherapy-induced bone marrow ablation beforehand. The CD3/CD45RA -depleted graft contained per kg of recipient weight 20.28×10^6 CD34+ cells, 5×10^6 CD45RO+ cells. The donor had antibodies against CMV, VZV, EBV, and herpes simplex. She received graft-versus-host disease prophylaxis with Cyclosporine. The transplant was uneventful.

Engraftment following HSCT was monitored

by daily counts of leukocytes, neutrophils, and platelets. Immune recovery was assessed post HSCT by FACS (Canto II, BD) of peripheral blood lymphocytes, using antibodies against CD3, CD4, CD8, CD19, CD56, CD45RA, and CD45RO (BD). Donor myeloid and T-cell chimerism was monitored by DNA genotyping of short tandem repeat polymorphisms (PCR-STR, 3500 Dx Genetic Analyzer, Applied Biosystems). The patient was evaluated for signs of acute and chronic GvHD.

The whole blood chimerism reached 9.61% on day +30 with the rise of peripheral lymphocytes count (Figure 1 and Figure 2). Rotavirus could be detected in stool specimens for another three weeks, but resolved after successful T-cell engraftment (300 CD3+ cells). The donor chimerism represents the memory T-cells, and NK cells infused in the CD3/CD45RA depleted graft. The fall in donor chimerism parallels the fall in lymphocyte count, although CD3+ comes up from day +60 to +90.

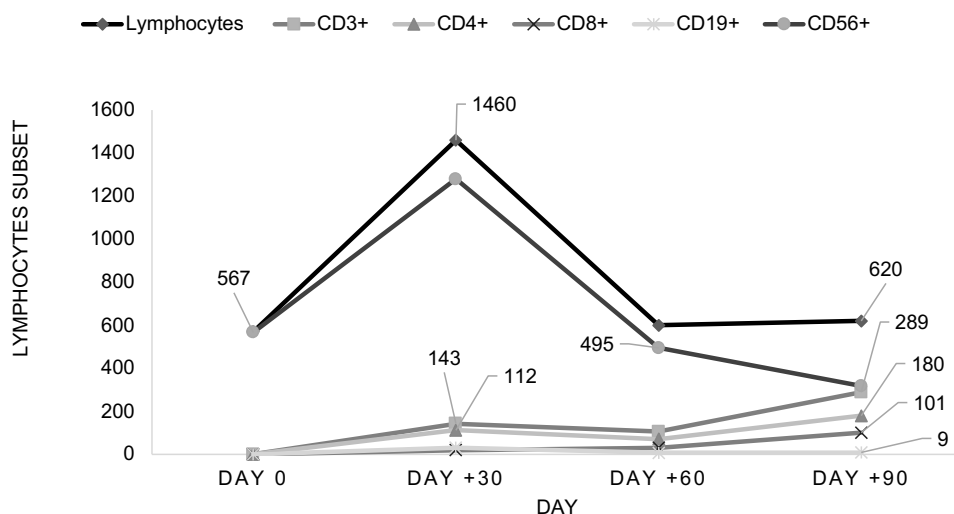


Figure 1. Total lymphocytes count and lymphocyte subset post 1st transplantation without conditioning

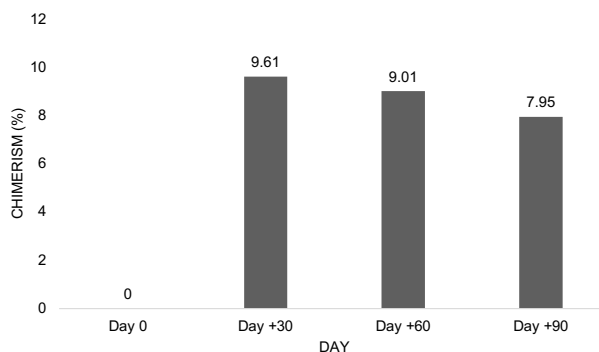


Figure 2. Whole blood chimerism post 1st transplantation without conditioning

Second transplantation

Three months post 1st transplantation, the patient gained weight (3kg/ 3 months), cleared of infection with normal renal and liver function, and was ready to move on the 2nd transplant. At 12 months old, she was conditioned with a myeloablative regimen, according to guidelines regarding HSCT for primary immunodeficiencies with a haploidentical family donor in patients older than three months.⁶ This consisted of i.v. anti-human T-lymphocyte immunoglobulin (Grafalon) given from day -9 to -6 (15mg/kg body weight/day), Fludarabine (40mg/m² BSA/

day, from day -5 to -2), and Busulfan (5.1mg/ kg body weight/day, from day -5 to -2). The only form of GvHD prevention was the immunomagnetic depletion of CD3/CD45RA+ cells from the graft. Cyclosporin post-transplantation was used for GvHD prophylaxis.

A cryopreserved portion of the CD3/CD45RA -depleted graft was infused for her with a stem cells dose of 20 × 10⁶ CD34+ cells, 2 × 10⁶ CD45RO+ cells per kg of recipient weight without any complication.

Engraftment and immunological reconstitution

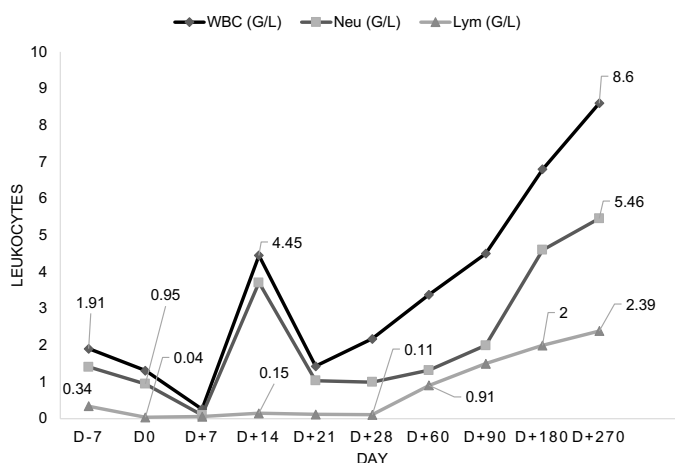


Figure 3. Total lymphocyte count (TLC) and concentrations of different lymphocyte subsets (indicated by CD positivity) over time about second HSCT

Hematological recovery post-HSCT was prompt with a white blood cell count >1 × 10⁹/L at day +11, neutrophils >1 × 10⁹/L at day +13

with G- CSF, and T- cells at day +13 (Figure 3). Thrombocytes > 50 × 10⁹/L at day +45. Complete myeloid and T-cell donor chimerism

was reached at day +28. Supplementation with immunoglobulins was discontinued on day +90 post-HSCT and she is clinically well. Her body

weight increased steadily and reached to 11kg 3 months after the 2nd transplant.

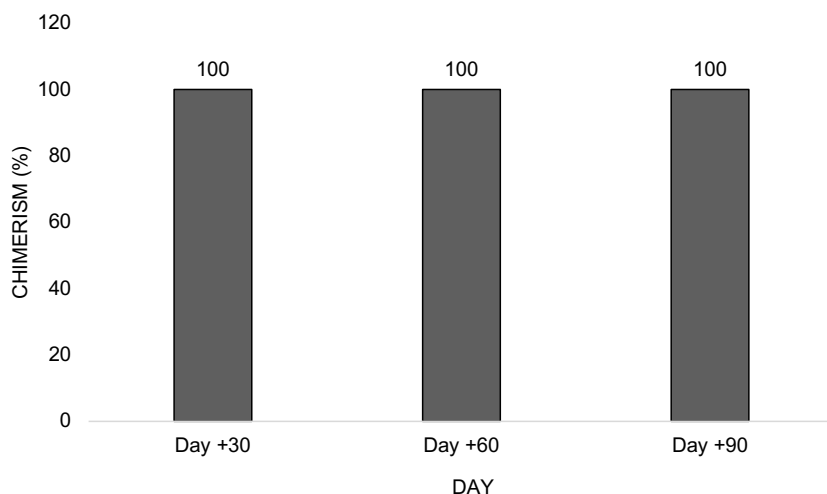


Figure 4. Whole blood chimerism post 2nd transplantation

Post-transplant morbidity

The early post-transplant period was complicated at day +5 by neutropenic fever with unknown etiology, which was resolved by Meropenem and Vancomycin. Acute GvHD of the skin was observed on day 16. Because it extended rapidly throughout the whole body, IV corticosteroid at 1mg/kg/day was given for three days, weaning slowly for two weeks. Complete myeloid and T-cell donor chimerism was reached at day +28. Supplementation with immunoglobulins was discontinued on day +60 post-HSCT. She has discharged approximately two months post-HSCT.

Four months after 2nd transplantation, she developed shortness of breath, wheezing, and dyspnea. Chest X-ray did not reveal any abnormality, but a chest computed tomography (CT) scan showed mosaic perfusion, bronchiectasis, bronchial wall thickening, and airflow obstruction. Cultures from bronchoalveolar lavage were positive for *Epstein-Barr* virus. Cultures from blood are negative for any pathogen;

blood PCR EBV and CMV were negative. Patient was diagnosed for Bronchiolitis obliterans and was treated with immunosuppression therapy (high-dose steroids, mycophenolate mofetil) and FAM protocol (Fluticasone, Azithromycin, Montelukast). She did not develop any sign of other clinical chronic GVHD.

At 12 months after HSCT, she is continuously on FAM protocol; her dyspnea improved.

III. DISCUSSION

We report a case of SCID female infant with persistent *Rotavirus* infection for whom HSCT resulted in T-cell engraftment and clearance of *Rotavirus*. Rotavirus infection persisted before transplantation despite oral immunoglobulin's administration. In fact, oral administration of immunoglobulin for treatment of *Rotavirus* gastroenteritis has been reported with some success.¹⁰ To our very best knowledge, this is the first report of a chronic gastroenteritis case with *Rotavirus* in an infant suffering from severe combined immunodeficiency in Vietnam.

Allogeneic HSCT is the only curative treatment available for SCID, although it is associated with a high incidence of severe infections and an increased risk of GvHD.⁸ Haploidentical HSCT protocols utilizing *ex vivo* T extensively- cell-depleted grafts have proven efficient in preventing GvHD.⁹ The remaining challenge of enhancing post-transplant immune-reconstitution has been addressed by several investigators by utilizing partially T- cell-depleted grafts or adoptive transfer of donor immune cells.⁹ Our patient received a CD3/CD45RA depleted graft from her haploidentical mother, following a reduced-intensity conditioning regimen with a short course of ATG and Cyclosporin for GvHD prophylaxis. Engraftment was rapid with complete donor chimerism.

Infections in SCID are challenging; Rotavirus gastroenteritis is often persistent and leads to chronic malnutrition, compromising transplant outcomes.⁵ SCID patients with active infections usually cannot tolerate toxicity, but unconditioned transplant for NK positive SCID does not favor stem cell engraftment and sustainable immune reconstitution. Giving immunocompetent lymphocytes, for example, T-cells is life-saving in this situation and helps to bridge over to definitive transplant procedure with conditioning. *Ex vivo* T- cell depletion enables us to deliver CD34+ and memory T-cells at the desired cell dose precisely, ; surplus cells can be cryopreserved for future use, thus saving costs and manpower.

Bronchiolitis obliterans syndrome is a progressive, insidious lung disease occurring in a subset of patients after lung transplantation and allogeneic HSCT.¹¹ Bronchiolitis obliterans syndrome results in advanced circumferential fibrosis and ultimate cicatrization of the small terminal airways, manifesting as new fixed airflow obstruction. Allorecognition of lung antigens is the suspected etiology of bronchiolitis obliterans

syndrome because lung transplantation and HSCT both involve alloimmunity- host (hematopoietic cells)-vs-graft (lung) disease for lung transplantation and graft (hematopoietic cells)-vs-host (lung) disease for HSCT.¹¹ Additionally, bronchiolitis obliterans syndrome occurs after HSCT ; it is typically accompanied by alloimmune manifestations in other organs (e.g., liver, eyes, or skin).

The National Institute of Health Consensus Development Project published in 2006 the first comprehensive attempt to define clinical criteria for the diagnosis of bronchiolitis obliterans:

- (1) absence of active infection,
- (2) decreased FEV₁ (<75% of predicted normal),
- (3) evidence of airway obstruction with a ratio of FEV₁ to forced vital capacity of less than 0.7,
- (4) elevated residual volume of air (>120% of predicted normal), or
- (5) an expiratory chest CT or lung biopsy that reveals air trapping (expiration) or bronchiectasis.¹² If a lung biopsy is not performed, another manifestation of chronic graft versus host disease is needed.¹²

Recently, studies with potentially less toxic treatments such as low-dose macrolide antibiotics, leukotriene receptor antagonists, and combinations of inhaled bronchodilators and glucocorticoids have led to pulmonary function test stabilization or stabilization or improvement.¹³ This combination was also suggested to halt the pulmonary decline and permit reductions in systemic steroid exposure.

Lessons to be learned from this case are

- 1) gastrointestinal problems can be a presenting sign of primary immunodeficiency diseases,³
- 2) clearance of rotavirus was associated with T-cell engraftment and function,

3) oral IG and IVIG prior to transplant could not eliminate the chronic infection thoroughly in SCID patient.

IV. CONCLUSION

In summary, we demonstrate the success of CD3/CD45RA depleted haploidentical transplant for SCID treatment. This case highlights that T- cell engraftment and function appear to have been necessary for clearance of rotavirus in SCID patient.

Severe combined immunodeficiency is the most severe type of primary immune deficiency. It often presents within the first year of life with severe infections and faltering growth. Without stem cell transplantation, SCID is fatal. Because a primary immune deficiency, such as SCID, is often made in the first year of life, it is essential to consider this diagnosis when treating children with prolonged diarrhea and faltering growth.

It's very challenging to transplant a SCID baby when infections are well established. The extensive tissue damage will lead to the adverse long-term outcome on organ function despite immune reconstitution. Diagnosis and hematopoietic stem cell transplantation before the onset of severe infections offer the best chance for the long-term survival of SCID patients, which can be achieved by newborn screening.

REFERENCES

1. A. Bousfiha, L. Jeddane, C. Picard et al. The 2017 IUIS phenotypic classification for primary immunodeficiencies. *J Clin Immunol.* 38 (2018), pp. 129-143.
2. Lipstein EA, Vorono S, Browning MF et al. Systematic evidence review of newborn screening and treatment of severe combined immunodeficiency. *Pediatrics.* 2010; 25:

e1226-35.

3. Kobrynski LJ, Mayer L. Diagnosis and treatment of primary immunodeficiency disease in patients with gastrointestinal symptoms. *Clin Immunol.* 2011; 139:238-248.

4. Saulsbury FT, Winkelstein JA, Yolken RH. Chronic rotavirus infection in immunodeficiency. *J Pediatr.* 1980; 97: 61-5.

5. Patel NC, Hertel PM, Estes MK et al. Vaccine-acquired rotavirus in infants with severe combined immunodeficiency. *N Engl J Med.* 2010; 362(4): 314-319.

6. GBD Diarrhoeal Diseases Collaborators. Estimates of global, regional, and national morbidity, mortality, and aetiologies of diarrhoeal diseases: a systematic analysis for the Global Burden of Disease Study 2015. *Lancet Infect Dis.* 17 (2017), pp. 909-948.

7. Dvorak CC, Cowan MJ, Logan BR et al. The natural history of children with severe combined immunodeficiency: baseline features of the first fifty patients of the primary immune deficiency treatment consortium prospective study 6901. *J Clin Immunol.* 2013; 33(7): 1156- 64.

8. Pai SY, Logan BR, Griffith LM et al. Transplantation outcomes for severe combined immunodeficiency, 2000-2009. *N Engl J Med.* 2014; 371(5): 434- 46.

9. Touzot F, Neven B, Dal-Cortivo L et al. CD45RA depletion in HLA-mismatched allogeneic hematopoietic stem cell transplantation for primary combined immunodeficiency: A preliminary study. *J Allergy Clin Immunol.* 2015; 135(5): 1303-9 e1-3.

10. Alexander E, Hommeida S, Stephens MC et al. The Role of Oral Administration of Immunoglobulin in Managing Diarrheal Illness in Immunocompromised Children. *Paediatr Drugs.* 2020 Jun; 22(3): 331-334.

11. Yoshihara S, Tateishi U, Ando T et al. Lower incidence of Bronchiolitis obliterans in allogeneic hematopoietic stem cell transplantation with reduced-intensity conditioning compared with myeloablative conditioning. *Bone Marrow Transplant.* 2005 Jun; 35(12): 1195-200.

12. Filipovich AH, Weisdorf D, Pavletic S et al. National Institutes of Health consensus

development project on criteria for clinical trials in chronic graft-versus-host disease: I. Diagnosis and staging working group report. *Biol Blood Marrow Transplant.* 2005; 11: 945-956.

13. Kim SW, Rhee CK, Kim YJ et al. Therapeutic effect of budesonide/formoterol, montelukast and N-acetylcysteine for bronchiolitis obliterans syndrome after hematopoietic stem cell transplantation. *Respir Res.* 2016; 17(1): 63.